

KERATOPLASTY "A CHAUD" RESULTS OF 52 CASES

BY

C. OERGEN, M. D. - COGAY, M. D.

Ankara - Turquia

Franchescetti and Deret ¹ suggested the term of "Keratoplasty a chaud" to a group of therapeutic keratoplasty, covering such cases as acute or recidivant keratitis, corneal ulcerations and burns and reported the results of 11 cases.

Although the term of "Tectonic" on prophylactic keratoplasty were used the pionners of the so called keratoplasty a chaud are Nizetic ², Löhlein ³, Filatov and Bajenova ⁴. These authours used eye saving corneal graft operations for different cases of acute corneal inflammations.

Paufique ^{5,6} used therapeutic lamellar grafts in cases of acute suppurative keratitis, herpetic keratitis, ulcerous keratitis, dystrophic condition and tuberculous and syphilitic keratitis and obtained good results.

De Voe ⁷ reported the results of 40 cases of therapeutic keratoplasty, Kato ⁸ used preserved corneal grafts in 4 cases of rodent ulcer and Gudkovo ⁹ reported successful results obtained in cases of severe corneal pyosis by preserved corneal grafts.

Rycroft ¹⁰ used the term of keratoplasty a chaud, synonymous with therapeutic grafts or grafts during evolution, and defined this kind of operation, as "being executed during the evolutionary period or corneal affection, whether this be an irritative, inflammatory or degenerative nature" and included the following

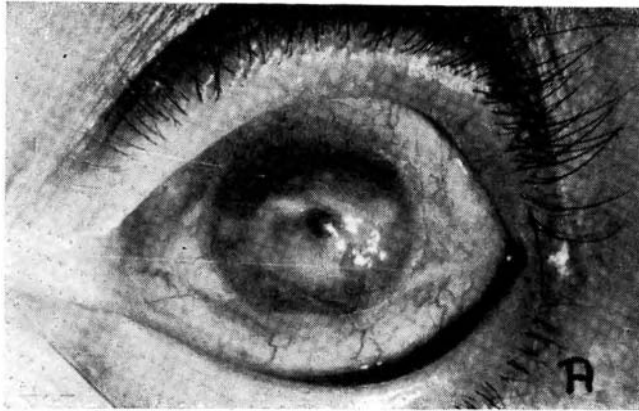


Fig. 1. A: Hypopyon ulcer resistant to treatment, L.E., in a 50-year-old male. Vision: L.P.

cases: Herpetic and disciform keratitis, torpid corneal ulcer, intracorneal abscess, acute interstitial keratitis, traumatic conditions and tumours.

In this article, excluding the cases of degenerative nature and tumours, we shall confine the subject to cases of active inflammations and ulcerations of cornea, in evolutionary period of the disease.

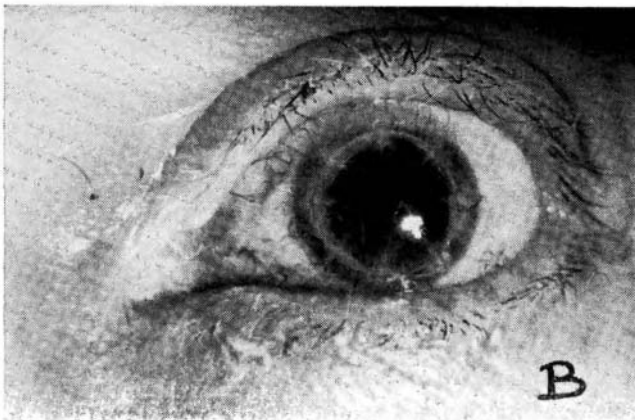


Fig. 1. B: Same eye, one mo. after a 8 mm. penetrating graft. Vision: 0.1

KERATOPLASTY

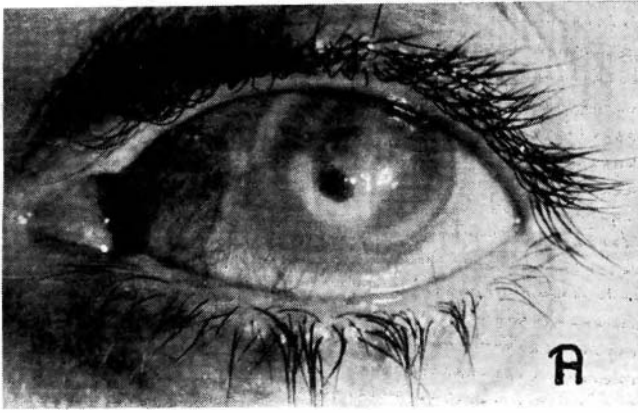


Fig. 2. A: Active keratitis and descematocele, L. E., in a 39 year old male. Vision: L.P.

During the last 2.5 years (1965-1967), in the Eye Bank and department of Ophthalmology of Ankara University 52 cases of therapeutic keratoplasty on active inflammatory stage were performed. This about 28.6%, of all corneal graft operations made in this period (52 out of 181 cases).

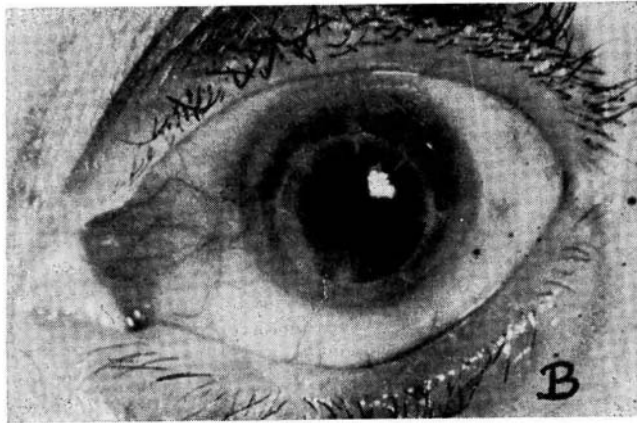


Fig. 2. B: Same eye, 2 mo. after a 7 mm. penetrating graft and synechiotomy. Vision: 0.1

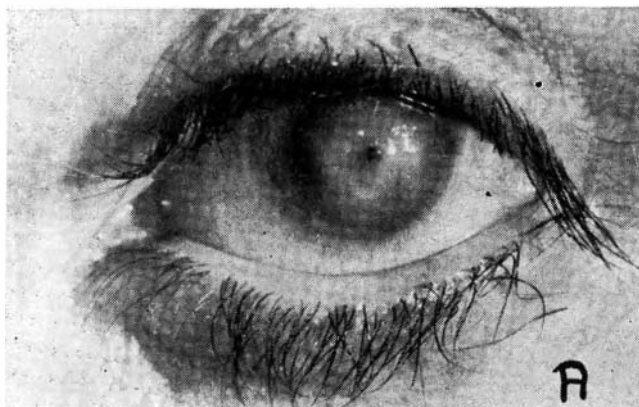


Fig. 3. A: Corneal fistula. L.E. in a 29-year-old male. 2 month ambulatory and 14 days of treatment in clinic failed. Vision: L.P.

7 cases had hypopyon ulcer, resistant to treatment. Local and systemic therapy, including paracentesis and irrigations of anterior chamber with antibiotics, had failed. Average duration of preoperative treatment was about 50 days (Table). In 2 cases post-operative synechiotomy performed. 5 clear grafts were obtained

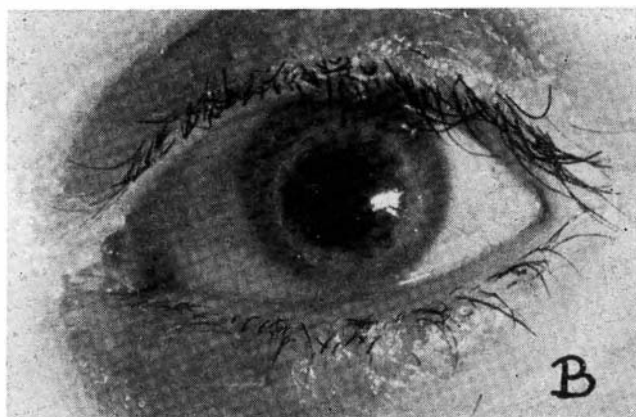


Fig. 3. B: Same eye, 5 mo. after a 7 mm. penetrating graft: 3 times synechiotomy and a peripheral iridencleisis. Ocular pressure 17 mm. Hg. Schiötz. Vision: After correction 0.6.

KERATOPLASTY

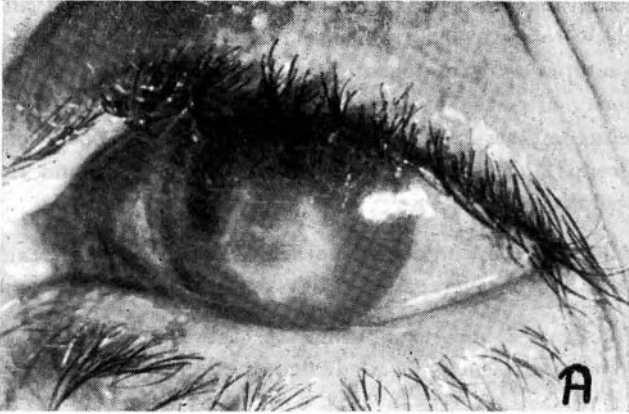


Fig. 4. A: Torpid herpetic ulcer of long standing. L.E. in a 40-year-old male. Vision: L.P.

(Fig. 1). 16 cases had active corneal inflammation and descematocele. 10 clear grafts were obtained (Fig. 2). 5 cases had corneal fistula. There were the most unfortunate cases. Massive anterior synechia, oclusio pupillae were common symptoms. After taking off the diseased part of cornea, the anterior chamber was irrigated with antibiotics. Fibrous membranous debris on the iris and lens

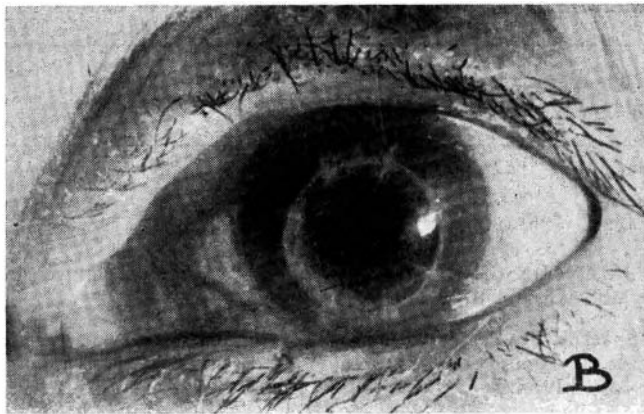


Fig. 4. B: Same eye, 2 mo. after a 7 mm. penetrating graft and a synechiotomy. Vision: 0.5.

were removed by on intracapsular forceps. Bleedings of iris were stopped and the peripheral parts of iris were separated from cornea. Then graft was placed and fixed with 16 direct sutures. Anterior chamber was filled with air through on amsler needle. In majority of cases some anterior synechias persisted. There were divided in 1-3 synechiotomy sessions. In some antiglaucomatous operations were performed. In this group 2 clear grafts were obtained (Fig. 3), and the other 3 had eye saving operations.

24 cases had metaherptic keratitis and torpid corneal ulcers. 18 clear grafts were obtained (Fig. 4). They had on average of 49 days treatment without result.

In all groups size of grafts varied between 6-9 mm. 36 cases (50%) had 7 or 8 mm. grafts. Only 5 lamellar grafts could be used, remaining being penetrating.

TABLE: RESULTS OF THERAPEUTIC GRAFTS

<i>Diagnosis</i>	<i>Nº of Cases</i>	<i>Average period of Preoperative Treatment</i>		<i>Number of Clear Grafts</i>
		<i>Ambulant</i>	<i>In Hospital</i>	
Hypopion ulcer	7	20 days	1 mo.	5
Descemetocele	16	1 mo.	13 days	10
Corneal fistula	5	40 days	10 days	2
Meta herptic keratitis and torpid corneal ulcers	24	36 days	13 days	18

REFERENCES

1. FRANCHESCHETTI, A., und DORET, M.: Hornhauttransplantation "a chaud", *Klin. Mbl. Augenheil.*, 117: 449-458, 1950.
2. NIZETIC, Z.: Versuch einer Hortaütübertragung bei einem Säugling, dessen Hornhaut durch Ophthalmoblennorrhöe eingeschmolzen war, *Klin. Mbl. Augenheil.*, 103: 32-35, 1938.
3. LOHLEIN, W.: *Dtsch. Ophth. Ges.*,
4. FILATOV and BAJENOVA (1938) cited by Leigh, A. G.: *Trans. Ophthal. Soc. U. K.*, 79: 439-452, 1959.

C. ORGEN - N. COGAY

5. PAUFIQUE, L.: The therapeutic lamellar corneal graft. *Trans. Ophthal. Soc. U. K.*, 69: 67-69, 1949.
6. PAUFIQUE, L.: Indications for the therapeutic lamellar corneal graft, *Am. J. Ophthal.*, 33: 24-25, 1950.
7. DE VOE, A. G.: Observations on reconstructive and therapeutic corneal grafting, *Am. J. Ophthal.*, 50: 1124-1130, 1960.
8. KATO, K.: Lamellar keratoplasty in rodent ulcer, *Jap. J. Clin. Ophthal.*, 18: 1319-1322, 1964. (Abst.) *Zentralbl. Gesam. Ophthal.*, 94: 223, 1965.
9. GUDKOVA, L. S.: Treatment of severe corneal pyosis by keratoplasty, *Vestn. Ophthal. (Mosk.)*, 77: 54-58, 1964. (Abst.) *Zentralbl. Gesam. Ophthal.*, 95: 145, 1965.
10. RYCROFT, B. W.: *Corneal grafts*. London: Butterworth, 1955, 83 p.

Ankara University Vehbi Koç