

# Conferencia del Recipiendario de la medalla de Oro “Ignacio Barraquer y Barraquer”

Prof. Relja Zivojnovic.

Profesor Jose Ignacio Barraquer and members  
of his family

Members of the Colombian and District Go-  
vernment

Honorary Presidents of the Congress

Special Guests, Dear Graduates

Members of the organizing committee and the  
Barraquer Institute

President of the Colombian Ophthalmological  
and Optometrical Societies

Ladies and Gentlemen

It is a great honour for me to be rewarded with  
the gold medal of Ignacio Barraquer y Barraquer  
for my contribution in the development of vitreo-  
retinal surgery.

Progress and success in very few human activities  
can be attributed to one individual only. Particu-  
larly in vitreo-retinal surgery this is not the case and  
therefore, on this occasion I want to mention those  
who have contributed to my success with their  
work and commitment. They are my colleagues  
and collaborators from the Eye Hospital Rotter-  
dam, especially the staff of the operating theatre,  
instrument workshop and photography. My par-  
ticular gratitude goes to my colleague Diane  
Mertens for cooperation and support in the long  
years of our work together. My appreciation is also  
directed to the small but faithful group of colla-  
borators, who accompanied me and continued  
working with me when I moved from Rotterdam  
to Antwerp. Last but not least I wish to thank my

Vitreoretinal surgery Dpt. of Ophthalmology A.Z. Middelheim

wife Vesna for her steady support and acceptance  
of all difficulties and changes in our life dictated  
by my professional career.

This medal carries the name of Ignacio Barraquer  
y Barraquer, the founder of the clinic and the  
Barraquer Institute.

He was a universal personality. Besides his other  
activities his particular interest in technique re-  
sulted in an enormous amount of techniques and  
instruments. He was a great teacher well known  
by his openness and generosity. But above all he  
probably was a happy and satisfied person. By his  
extraordinary career and achievements he justified  
expectations of his father, Jose Antonio Barraquer,  
the first professor of ophthalmology in Barcelona.  
Besides he handed over his work as inheritance  
to his descendants. The fourth Barraquer  
generation is treading now his fascinating path.

At the time of my residence in the Eye Hospital  
Rotterdam, in the early sixties, the name of  
Barraquer was the most frequently used name in  
our operating theatre. We were using Barraquer  
Colibri blepharostat and forceps and mosquito  
needleholder. Erysiphak was not replaced yet by  
the cryo-extractor, Alpha-chymotripsin was used  
routinely with cataract extraction. Virgin silk was  
the most suitable material for corneoscleral suture.  
And all that was related to the name of Barraquer.  
As a young specialist, having spent three previous  
years at general surgery in Yugoslavia and  
Germany, I had a special interest in surgery, and  
at that time the name of Barraquer was for me the  
symbol of progress and inventiveness in oph-  
thalmic surgery.

Although, due to my dedication to the vitreo-  
retinal surgery, this first contact had not been

maintained, I was much interested to visit Barraquer's Institute during my first visit to Bogota in 1986. I was deeply impressed, and everything I saw corresponded to my expectations. However, two matters sank deeply in my mind.

First, at the outpatient clinic, I saw separate waitingrooms for private and poor patients on the opposite sides of the building. But in the middle were the examination rooms equipped with the most up-to-date devices in which the same staff members were working with both groups of patients.

Second, I saw a room equipped with microscopes in which residents were operating on cadaver eyes or animals supervised by staff members, preparing for surgery on patients after a sufficient number of such operations.

Surgical education of residents in such a responsible way is, to my knowledge, unknown in Europe, and if it does exist somewhere, then it is a great exception and not a rule.

Both above-mentioned matters may be used as proofs for humane, social and realistic approach in otherwise professional work at the highest level.

To recount the development of my contribution to treatment of vitreo-retinal pathology, which is the suggested theme of my lecture, allow me to begin with the description of the situation in the Eye Hospital Rotterdam at the time of my residency. My start as a resident in Rotterdam coincided, by chance, with the retirement of Professor Flieringa, who was a surgeon "pur sang" with a distinct interest in anterior segment surgery and very little respect for the other, non-surgical disciplines. Eye Hospital Rotterdam was a private, non-profit institution with loose ties to the university. Owing to Professor Flieringa and a monopolist position in the region, it developed into a place with a huge number of patients and operations. Professor Flieringa's successor, Professor Harold Henkes tried immediately to change the image of the hospital by stimulating and developing more theoretical disciplines such as electrophysiology, genetics and diagnostics of degenerative pathology of the fundus. Very soon in this new trend a new belief was established, that

surgery is daily routine work, everybody's burden, which can and must be done by all of us, and those who want to prosper have to do more than that.

Following the new trend the best residents applied themselves to the research of rare and serious hereditary diseases, producing - with the help of electrophysiology, fundus photography and genetic research - marvellous theses. The Netherlands, as a highly civilised country, for centuries without destructive wars, and with its 500 years old civil records is indeed a country par excellence for genetic research. In my own country civil records could never survive for more than 50 years.

With my surgical background and my preference for surgery as well as my lack of affinity to the mentioned disciplines, I was in the above mentioned situation rather frustrated and lost. Regarding good opportunities for practical work I decided, though, after my residency to stay another year at the Clinic as a junior staff member before my return to Yugoslavia. My only recommendations for this function were reliability and commitment to work.

My new position was very bizarre and I was immediately in charge of thirty beds and as subspecialties did not exist at that time, I operated all pathology admitted to my ward without any system. Supervision by the few senior staff members was restricted, but it was always possible in case of doubt and hesitation to call one of the senior staff members, who despite the burden of their own work and lack of time were always ready to help. In this way I was confronted with many surgical problems carrying responsibility for them.

In that situation I was also expected to perform independently retinal detachment surgery, not having - as more of us at that time - any special training for it. Retinal detachment surgery was then on the list of priorities behind the mentioned new disciplines and behind anterior segment surgery, which were on a high level. It was neither better or worse than in many leading hospitals in Europe. And that means it was bad. Encircling procedure and shortening of the sclera were performed as techniques, cryopexy was done under monocular indirect ophthalmoscope-binoscope. There were

a lot of recurrent detachments and they were a nightmare for surgeons who tried in any possible way to avoid or postpone a new operation.

Patients with both eyes closed were positioned in bed for weeks. When the possibilities of positioning with or without a cushion were exhausted, it was time for bricks to be put under beds. Doctor Beekhuis has illustrated that situation with the following slides. (Fig. 1, Fig. 2).

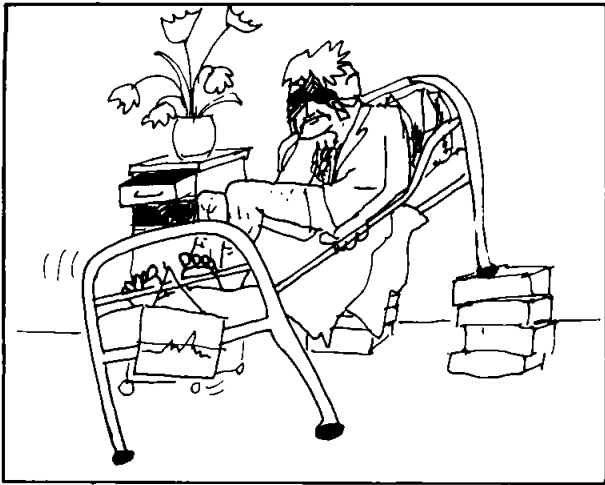


Fig. 1 Positioning in case of leakage of an inferior retinal tear



Fig. 2 Positioning in case of leakage of a superior retinal tear

Frequently after the last so-called successful operation - the retina attached, counting finger vision - the patient's mobility was restricted for months and he had to come for a check-up in the wheelchair. And to increase this misery, he also had to wear Lindner stenopaeo glasses for 3-4 weeks, as it is illustrated in Doctor Beekhuis's cartoon (Fig. 3). This depressing situation obviously could not be satisfying, and I tried to change and improve it by reoperating patients earlier and introducing new techniques. In my attempts to improve the level of the surgery by introducing new techniques, changing policy of the treatment and by long and exhausting operations I had very stimulating support of the senior staff. And as nobody was happy with that surgery, after a short time I had the divided pleasure of operating most detachments and difficult cases in the hospital.



Fig. 3 Waiting for the first check-up after the successful operation

After two and a half years of hard work and mostly self education I returned to my native country. A few years spent in Yugoslavia, where

I worked as a general ophthalmologist with little opportunity to use my experience in posterior segment surgery, did not satisfy my professional ambitions, so that in 1972 I returned to Eye Hospital Rotterdam.

On my return I was enabled to continue my work on detachment surgery and after a certain time I was able to ascertain that the level of surgery was significantly improved.

Success rate rose, the number of re-operations declined, and what was important, patients got rid of the above-mentioned torture. At the same time I was able to assert that for a certain number of difficult cases our surgical possibilities could not offer any solution. Visiting famous centres for detachment surgery such as Bonn, Essen and Lyon, learning always and everywhere, I saw that they could not pass a certain limit-line in treatment of retinal detachment. That limit-line were the difficult cases of retinal detachment with the immobile retina and vitreous organization. During a (lengthy) sabbatical in England I visited John Scott in Cambridge. At that time - I am talking about the middle seventies - John was the only surgeon in Europe who seriously and persistingly treated the inoperable cases of retinal detachment. Watching his surgery I was extremely impressed not only by his insight in this difficult pathology and by his surgical skills, but particularly by his devotion and commitment to his work.

At this moment I would like to make a digression and to say a few words about the development of vitreo-retinal surgery.

Retinal detachment surgery, based on Gonin's principles of closing retinal hole made a significant progress in the fifties owing to Custodis' method of episcleral buckle and Arruga's equatorial cerclage. But although the results were improved significantly, it was obvious that even with these new methods it was not possible to cure a certain number of difficult cases. The reason was a process which led to shrinking of the vitreous and fibrosis and immobilization of the retina. As a result of the process the relations between the retina and the vitreous were visibly disturbed on a large scale, so that an operation from outside could have no effect (Fig. 4.). Introduction of the intravitreal air

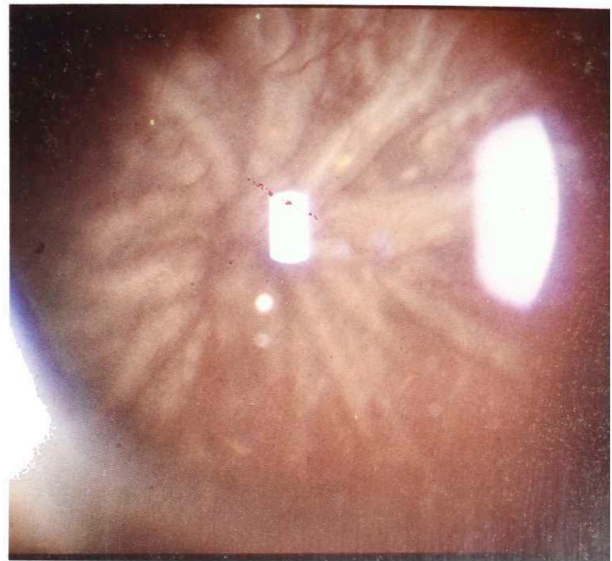


Fig. 4 Total retinal detachment with closed funnel

injection by Rosengreen was a logical attempt to approach the problem from another side, but in itself it was insufficient in treatment of difficult cases. The breakthrough came from the side of Paul Cibis, who introduced silicone oil into vitreo-retinal surgery in the early sixties<sup>1, 2</sup>. Cibis tried to use hydraulic power of silicone oil as an instrument (Fig. 5, 6). Expansion of silicone oil, which due to the surface tension remained in the form of a bubble, was observed in the indirect picture by binocular ophthalmoscope. In this way he managed to separate fibrotic membranes from the retina and to press the retina against the pigment epithelium. To make place for the injected silicone he evacuated subretinal and intravitreal fluid. After re-attachment of the retina he left the silicone in the eye as a permanent tamponade. In this technique he operated several patients (Fig 7), inoperable according to the norms of that time, and achieved convincing results. His pioneering work was unfortunately stopped by his early death in 1965 and his method survived only owing to John Scott, who took it up in the early seventies and improved further<sup>3,4</sup>. He introduced the vitreous scissors and flute needle for fluid evacuation as active manual surgery and much improved the technique and results. This technique in his hands was the only hope for many difficult cases for a number of years.

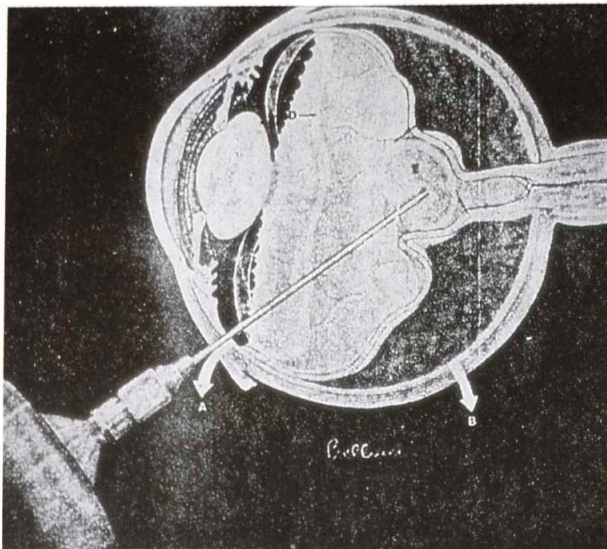


Fig. 5 y 6. Injection of silicone oil following Cibis' technique

Parallel to the described development, at nearly the same time, another approach to the solution of the problem was taking shape, namely removal of the vitreous. For a long time the vitreous had been the greatest enemy of ophthalmic surgeons; the prolaps of the vitreous in cataract surgery often resulted in fatal complications. The vitreous was a great tabu and every surgeon tried to avoid getting involved with it. There were rare such inventive surgeons as Ignacio Barraquer, who

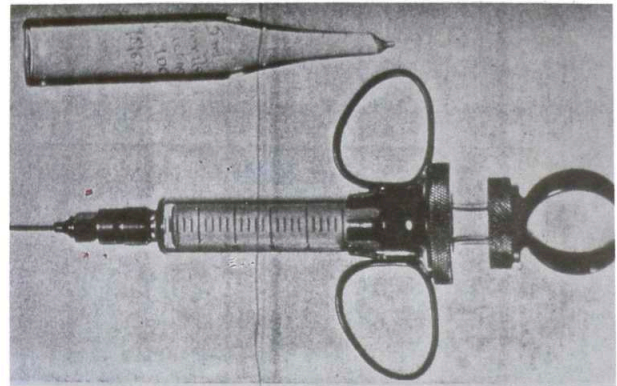


Fig. 7 Cibis syringe for injection of silicone oil

already in 1946 advocated a more active approach to the treatment of vitreous prolaps, advising excision, reposition and air injection in the anterior chamber.

The break-through was made by David Kasner, who was the first surgeon who intentionally removed the diseased vitreous. He performed this as a routine in a few cases and proved, that it can be tolerated by the eye<sup>5</sup>. His so-called "open-sky vitrectomy" method, although, basically revolutionary, had a lot of shortcomings; it was necessary to remove the lens, anatomic structures did not have normal relations, the instruments were not adequate etcetera. All this inspired Robert Machemer, who was working close to Kasner at that time, to solve these problems, introducing, in 1971, new and spectacular technique, pars plana vitrectomy, which will mark a new era in ophthalmic surgery<sup>6</sup>. The main principles of the new technique were vitreous removal by a cutting instrument, which is introduced into the eye through a small scleral incision. The described procedure is performed with the controlled eye pressure and observed through upright image of an operating microscope. The action is directed straight to the diseased tissue and there is no need to remove a clear lens. Main indications for the new technique were haemorrhages and vitreous opacities of various etiology.

In the middle-seventies it became clear that the expectations related to pars plana vitrectomy, concerning the treatment of difficult cases of re-

tinal detachment, were not fulfilled, so that gradually the interest arose in the Cibis-Scott technique and the use of silicone oil. It was also a logical step to combine these two methods. It was done in Paris in 1976 by Jean Haut, who used silicone oil mainly as tamponade after vitrectomy.

I introduced silicone oil in my surgery in the beginning of 1978 after I was convinced of effectiveness of the technique due to several visits to John Scott. At the same time we started with vitrectomies at the Eye Hospital Rotterdam. I operated a few hundred cases using Scott's technique with the binocular ophthalmoscope and without vitrectomy (Fig. 8 and 9). I did pars plana

vitrectomy only in cases with opaque media. The results were not bad, at least for some time after the operation (Fig. 10 and 11). After a certain time I came to the conclusion that the advantages of bimanual pars plana vitrectomy with the possibility of removal of the diseased vitreous and fibrotic tissue are superior to Scott's method, so that I abandoned it completely.

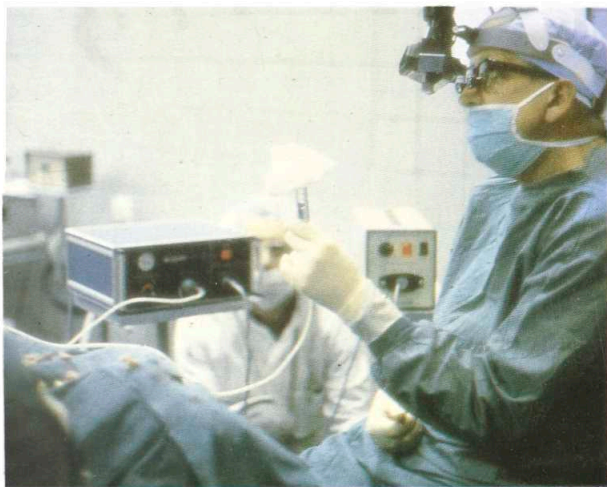


Fig. 8 Preparation of silicone injection

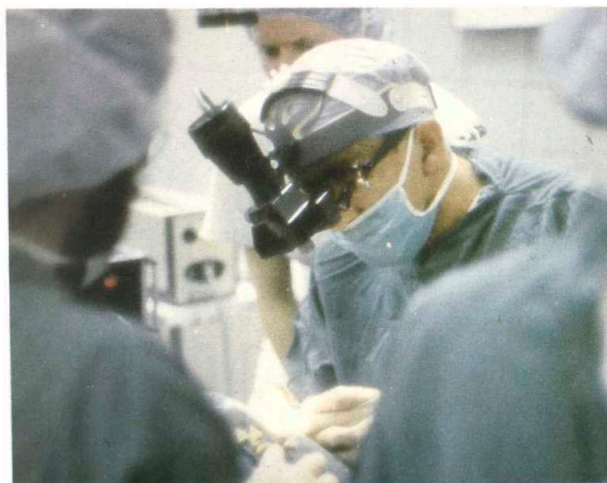

Fig. 9 Operation under the binocular ophthalmoscope

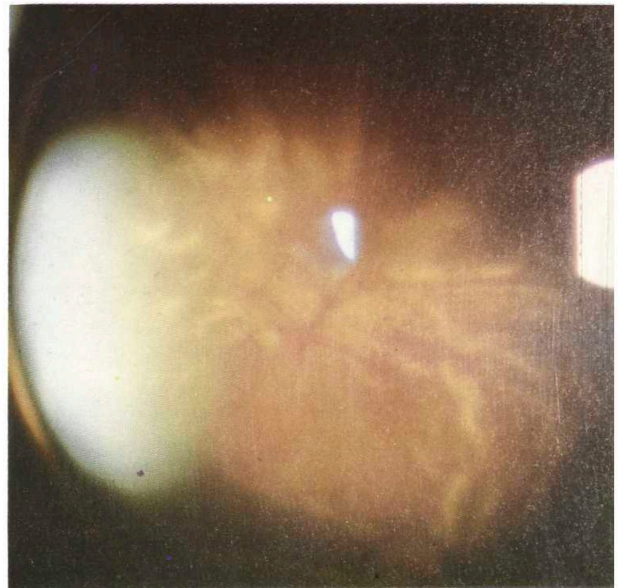


Fig. 10 A case of retinal detachment with PVR

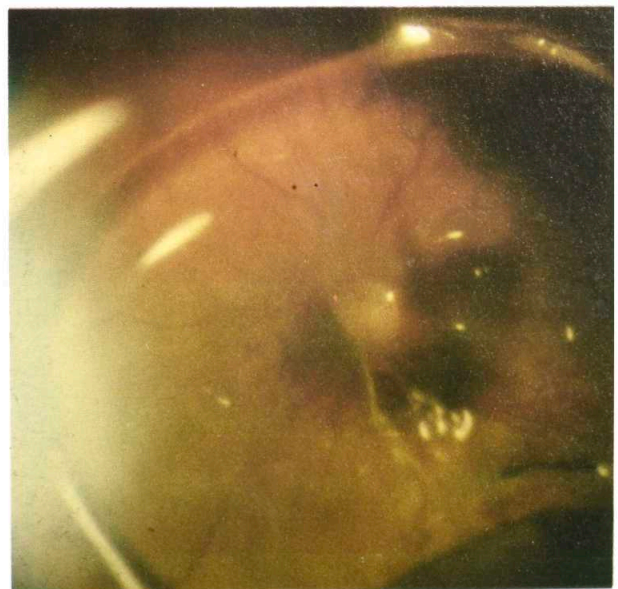

Fig. 11 The same case after the surgery

Operating more and more difficult cases proved that in the most difficult cases removal of vitreous and all proliferative tissues as well as cleaning of the retina were not sufficient to get the retina attached. In these cases the retina was either contracted or incarcerated, and sometimes detached due to existence of subretinal strands and proliferations. It became obvious to me that without surgical treatment of the retina itself such cases could not be solved (Fig. 12 and 13). At that

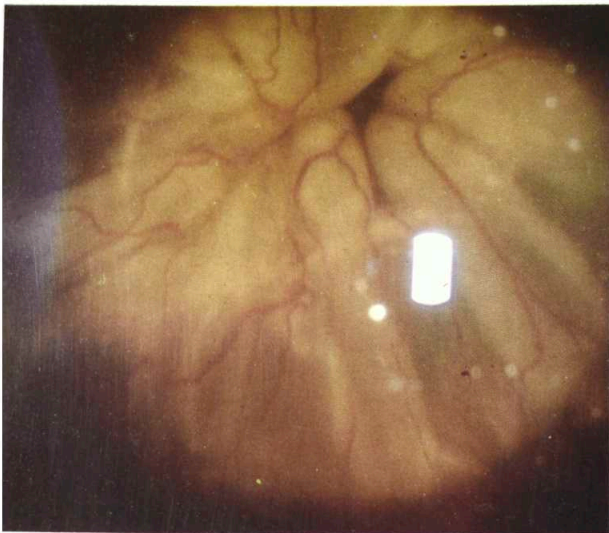


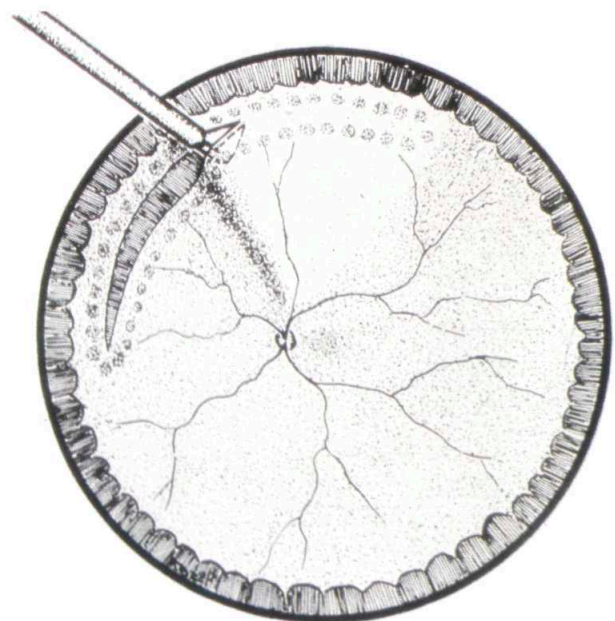
Fig. 12 A case of retinal detachment with subretinal proliferation before the silicone oil injection

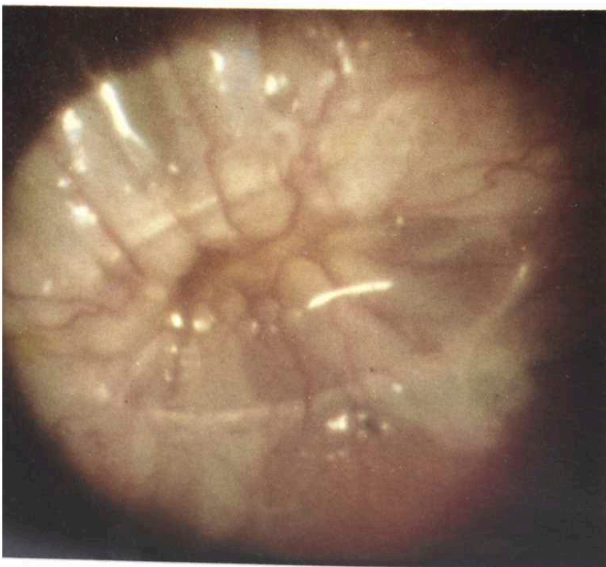

Fig. 13 The same case after the failed operation

time, in spite of an almost 10-year experience with vitrectomies, the retina was still a surgical tabu, and a fear existed with surgeons to damage the retina during operation. This rule was trespassed only sporadically and in cases of the greatest necessity<sup>7</sup>. Arrived at that decision after having to give up on the sole remaining eye of a few young patients following exhausting operations and application of all possible contemporary techniques, it was easier to decide because of certainty of permanent tamponade with silicone oil at the end of the operation, which greatly guaranteed the postoperative anatomic position. Owing to a large number of difficult cases, very soon it was possible to introduce retina surgery into our daily surgical work.

Already in 1980 I started performing retinotomies with extraction of subretinal strands, retinectomies of the peripheral retina with the contracted retina in giant tears and circumcision of big posterior chorioretinal scars (Fig. 14 and 15), (Fig. 16 to 23).



14. Retinotomy after diathermic coagulation of the retina

After the introduction of peripheral retinotomy logically followed the problem of fixation of the retina prior to the silicone oil injection. Inspired by a Japanese paper on sutures with giant tears<sup>8</sup> and



Fig. 15 Removal of subretinal strands through large peripheral retinotomy

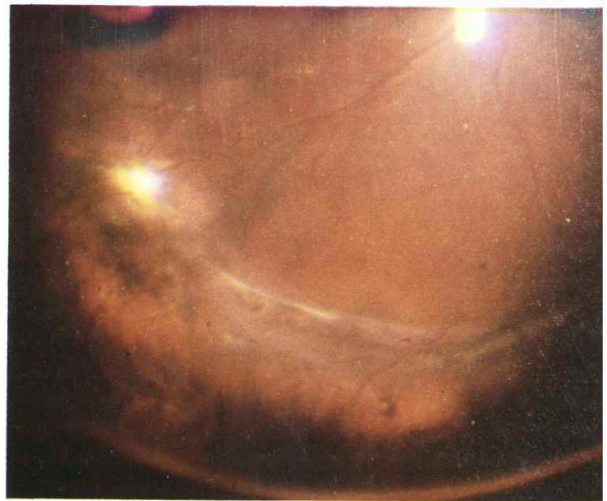
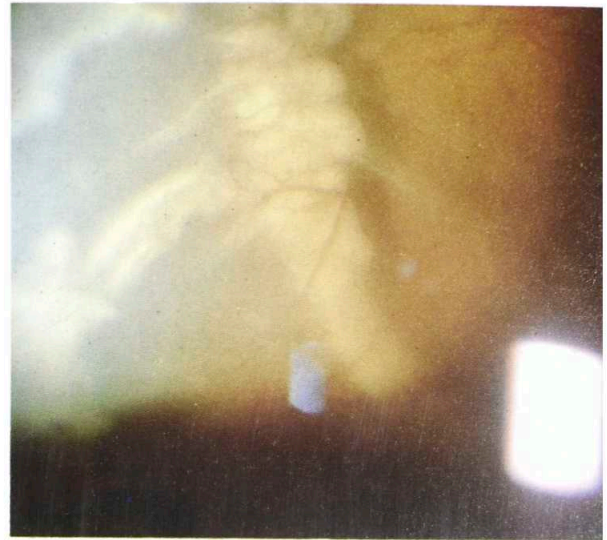

Fig. 18 y 19. The same case after the treatment and after removal of silicone oil

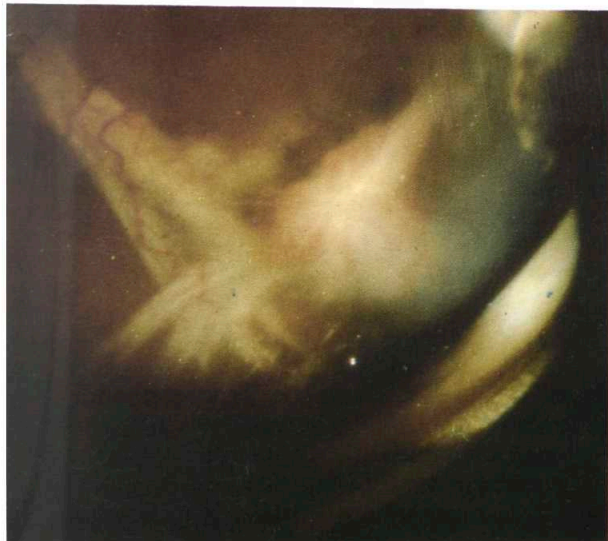


Fig. 16 y 17. Massive subretinal strands after double perforation

following the old principle of the Singer sewing-machine I invented a method with transvitreal continuous suturing of the retina (Fig. 24, 25, 26 and 27). This method, though very time-consuming, served well in about 20 difficult cases. (Fig. 28 and 29). In 1983 Ando published the

method of permanent retinal fixation with plastic tacks<sup>9</sup>. As I did not see the necessity of permanent mechanical fixation of the retina, I took over this excellent idea and constructed metal tacks, which were only used as an instrument during the operation, and taken out after the injection of silicone oil at the end of the operation (Fig. 30, 31, 32 and 33). This technique was popular for many years, but also compromised by many surgeons due to erroneous use. I used it successfully until perfluorocarbon was introduced three or four years ago (Fig. 34 and 35).



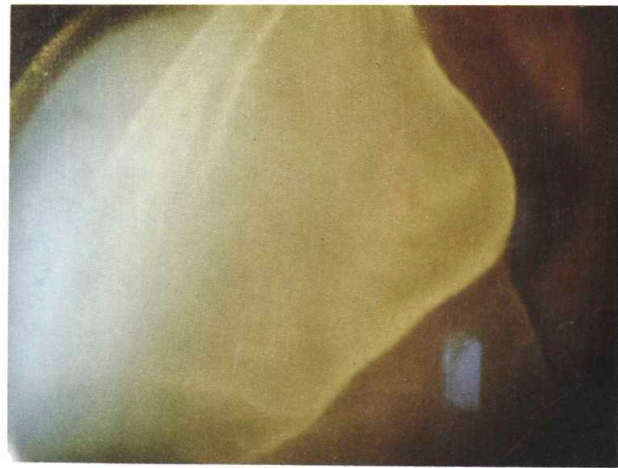
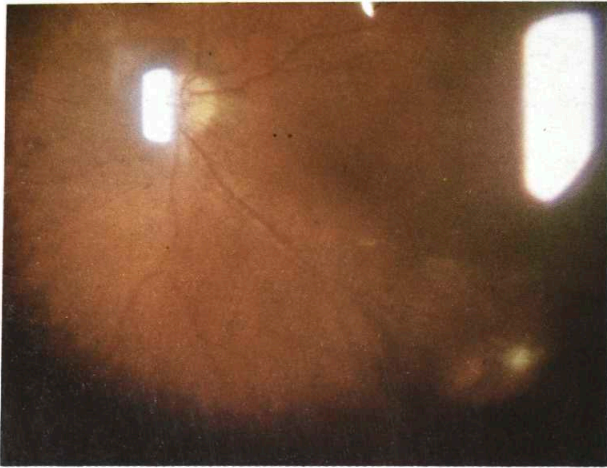


Fig. 20 A giant retinal tear

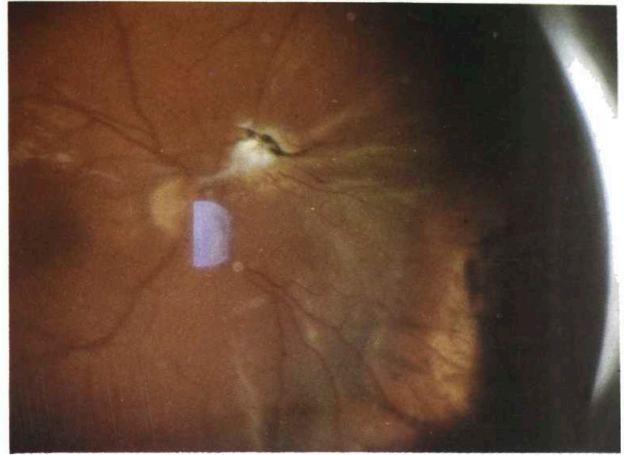
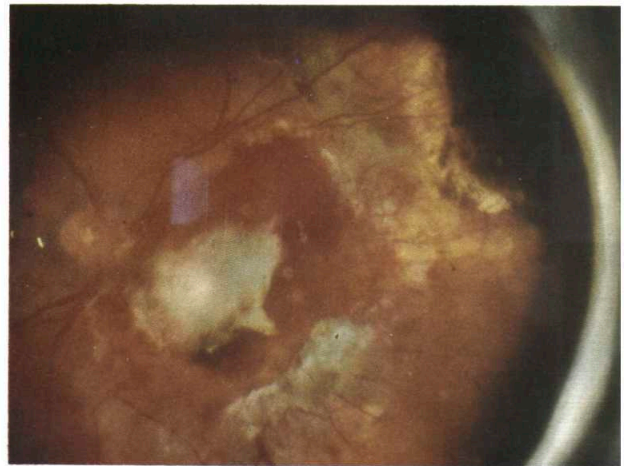


Fig. 22 Tractional retinal detachment after double perforation



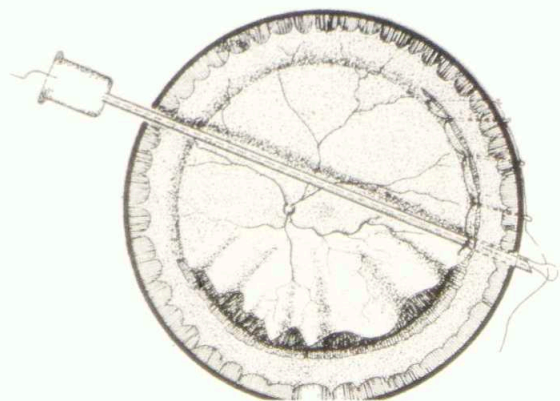


Fig. 26 y 27 Modified disposable needle for suturing of he retina

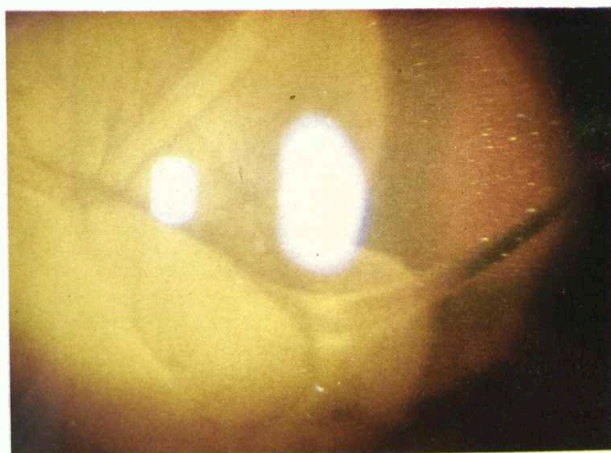


Fig. 28 A case with a 360 degrees giant retinal tear after perforating trauma

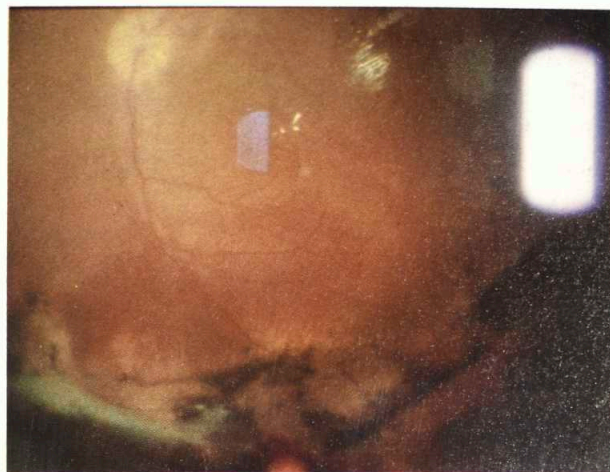



Fig. 29 The same case after vitrectomy and 360 degrees suturing of the retina



Fig. 30, 31 y 32 Metal tacks for temporary fixation of the retina



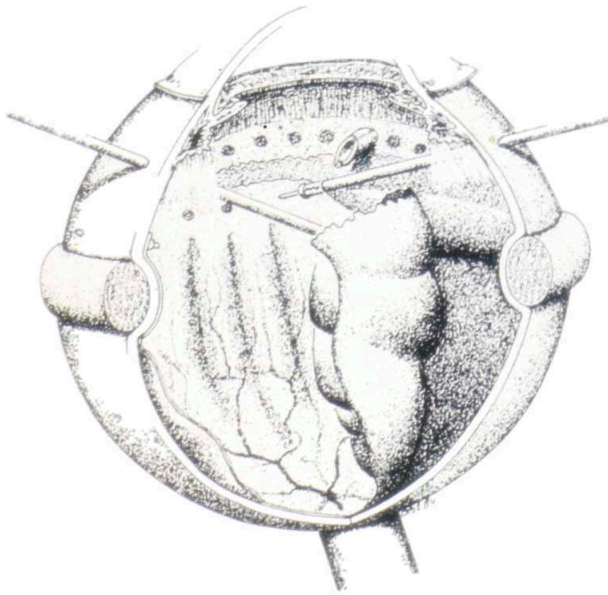


Fig. 33 Illustration of the use of retinal tacks

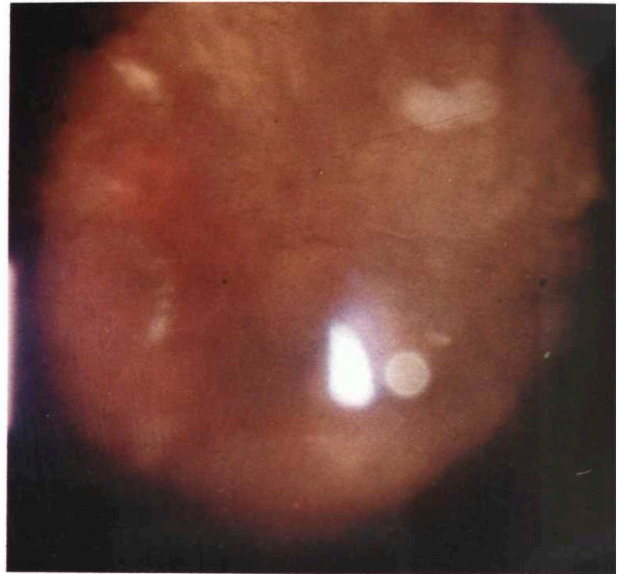

Fig. 35 The same case after the use of retinal tacks, vitrectomy and silicone oil injection

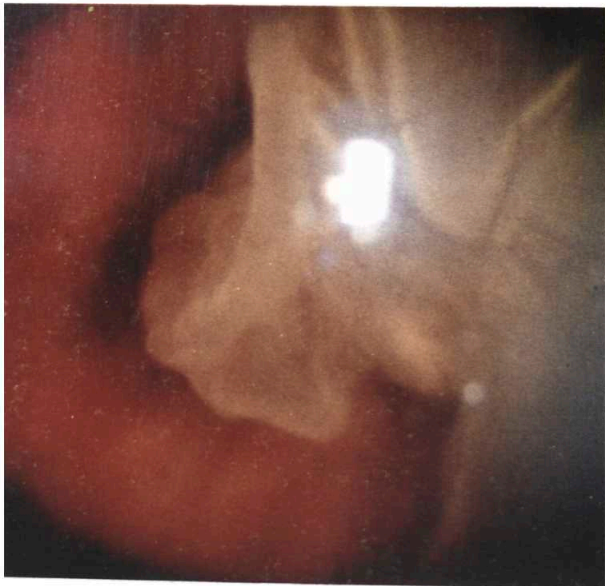


Fig. 34 A case of a giant retinal tear with the contracted immobile retina

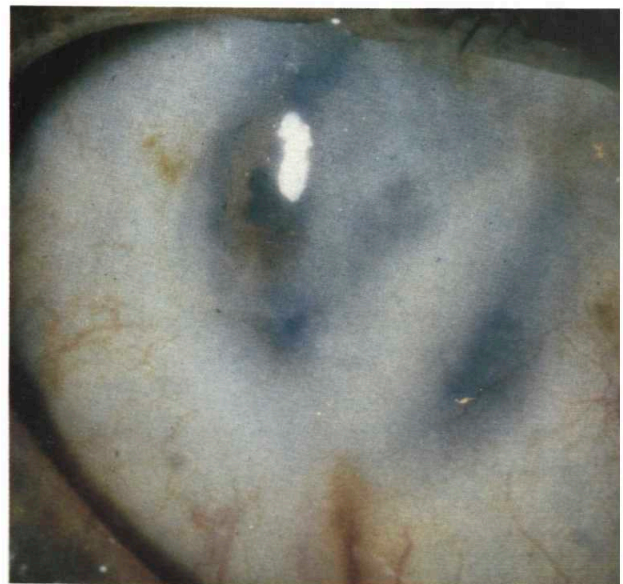

Fig. 36 y 37 Cases of a severely traumatized eye with destruction of the anterior segment and long-standing retinal detachment

Another surgical problem was severely traumatized eyes with destruction of the anterior segment and an old retinal detachment (Fig. 36 and 37). In the combination of reconstruction of the anterior segment, use of temporary keratopros-

thesis by Landers or Eckardt, (Fig. 38) pars plana vitrectomy and extensive retinal surgery, it was possible to operate successfully even these most difficult cases (Fig. 39 - 46).

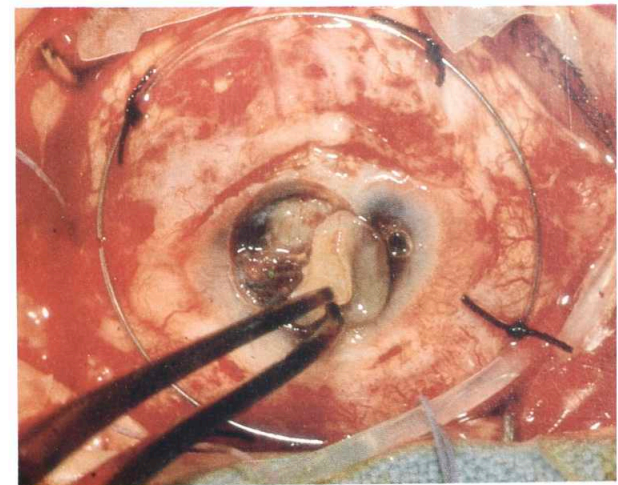

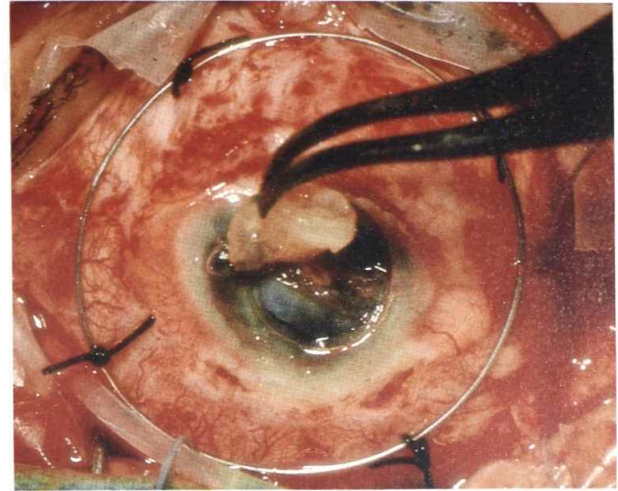
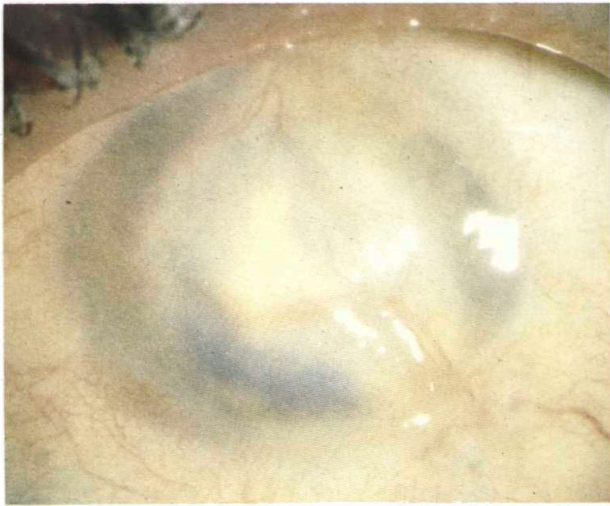


Fig. 38 Landers and Eckardt temporary keratoprosthesis

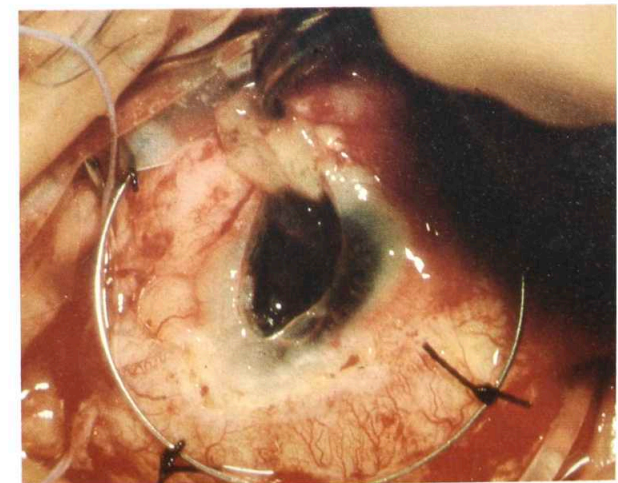
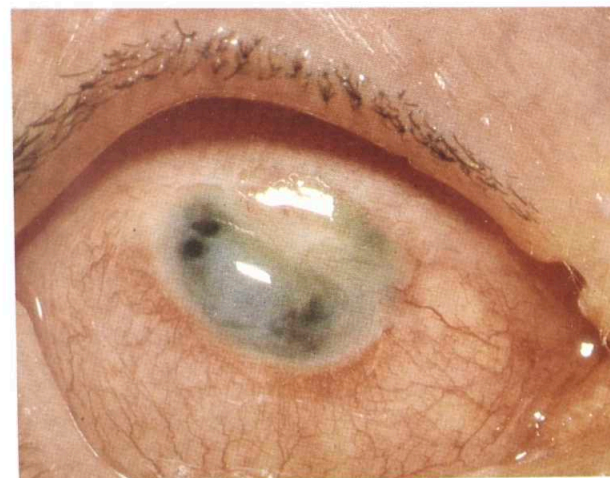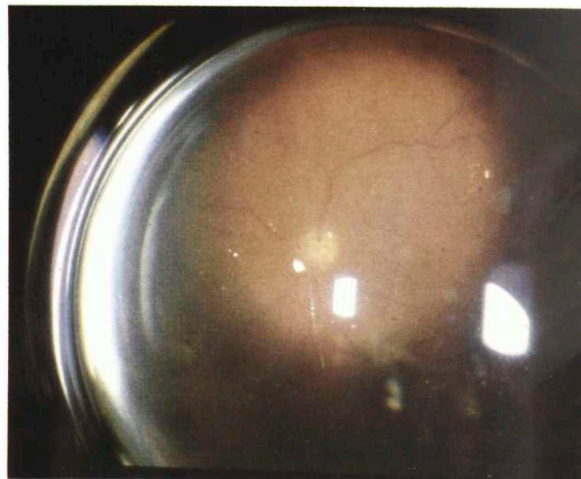
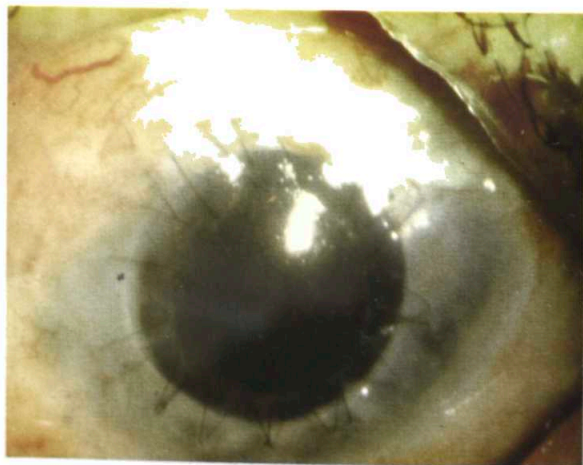
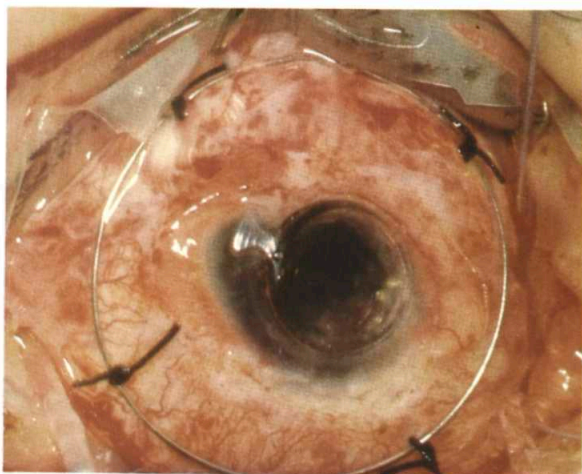
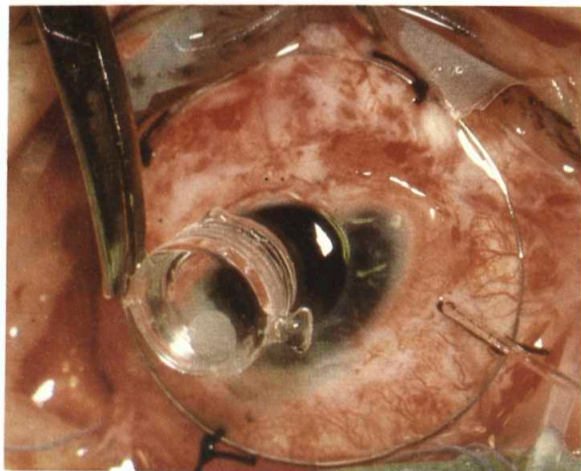


Fig. 39 y 46. A case with destruction of the anterior segment and long-standing retinal detachment (1 year after the injury) - operation and final result



It is easy to understand that corresponding instruments were necessary for performance of the above-mentioned complicated techniques.

Curiously enough, in 1979, when I started doing the complicated surgery, intravitreal surgical instruments for vitrectomy were very scarce. Besides, naturally, various types of vitrectoms, they consisted mostly of vertical scissors, Charles' flute needle for evacuation of fluid and blood and a bent hypodermic needle for membrane peeling. Using the ideal situation of having an instrument workshop in the hospital it was possible for me to follow the decribed development of surgical technique by the development of instrumentation. In the fertile - and still existing - cooperation with Mr. Vijfvinkel, who was head of the workshop at that time, we first replaced the silicone screw driven syringe with the silicone injector (Fig. 47 and 48). Then in rapid succession we constructed a fair number of forceps, various types of spatula and scissors, modified twice the classical Charles' flute needle (Fig. 49, 50, 51 and 52), constructed the mentioned needles for suturing of the retina and the retinal tacks. In that fascinating time of developing surgery and accompanying instruments, Ger Vijfvinkel, following and understanding problems of the surgery, was not only a manufacturer but frequently a co-inventor of new instruments.

Having introduced new surgical techniques it




Fig. 47 Hand-driven syringe for injection of silicone oil




Fig. 48 Injection pump for silicone oil

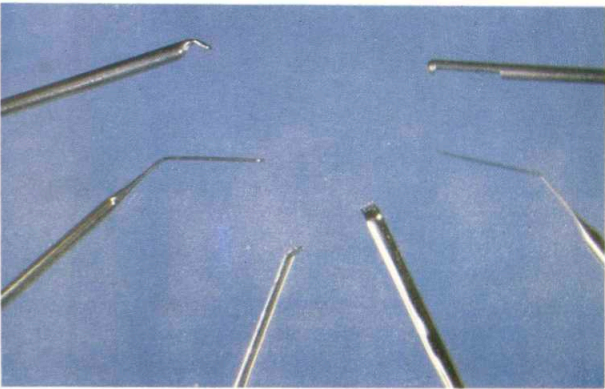


Fig. 49 Various types of spatulae

became possible to treat successfully even those cases which were absolutely inoperable before. At the same time, practising this extreme and aggressive surgery, and exhausting to the very end surgical possibilities of the treatment I have become aware of two facts. First, in spite of the success, in all these cases the surgery was indeed the only possible but also a very inadequate treatment, since the basic problem is not a surgical but a biological one. Consequently there is a great number of redetachments and re-

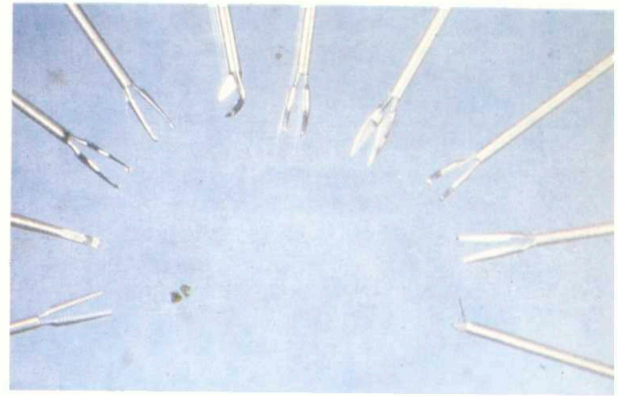


Fig. 50 Scissors and forceps

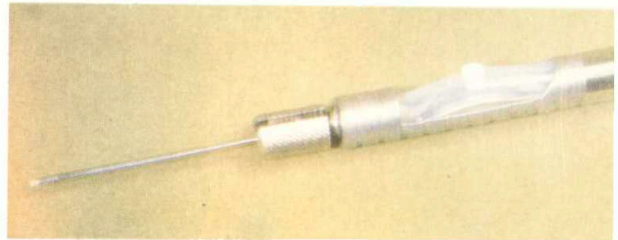

Fig. 51 Back-flush needle

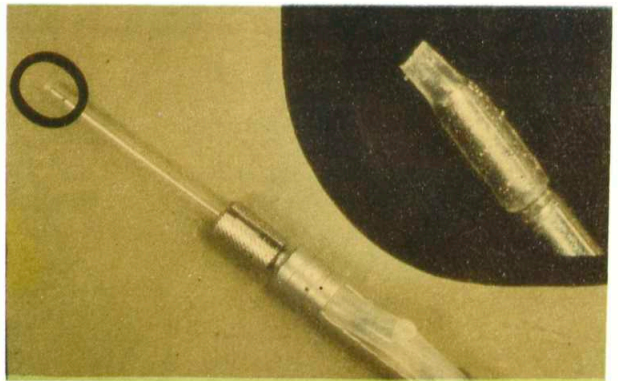


Fig. 52 Back-flush needle with the silicone tip

operations because of re proliferation. Second, which is the consequence of the first, introducing this new extreme surgery, which is though indispensable, still very traumatizing, we introduced a new stimulan for re proliferation, due to the iatrogenic trauma. Therefore it is necessary to remark that surgical treatment of the retina is, in principle, the last step which has to be done only when all the preceding possibilities have been

exhausted, such as vitrectomy, membrane peeling and removal of fibrotic tissue, and the attachment of the retina has not been achieved. Danger of this surgery, which requires experience and serious and ethical approach; is illustrated by the following horror pictures, which are the proof of inadequate application of retinal surgery (Fig. 53 and 54).

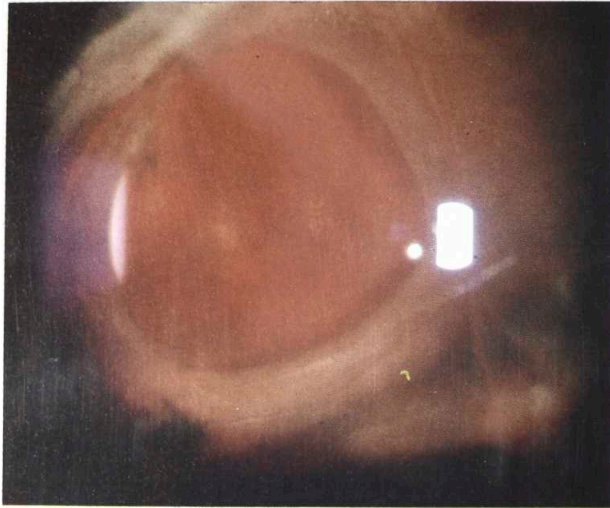


Fig. 53 A large retinal tear after the failed operation

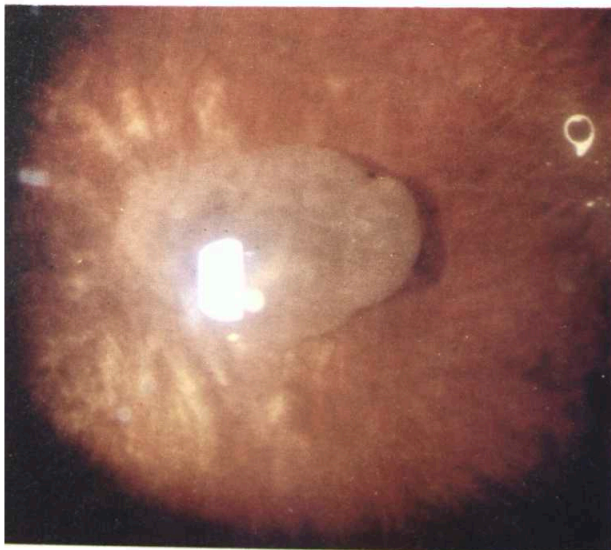



Fig. 54 A completely contracted retina after a 360 degrees retinotomy and the failed operation

Improved results and particularly my readiness to operate even the cases with an utterly small

chance of success resulted in the inflow of a great number of patients, specially from my own country. (Fig. 55).



Postoperative functional results in particular immediately after the operation were very modest. My and the patient's justified desire for the best possible result was thus observed by Doctor Beekhuis, from his superior position of the anterior segment surgeon, (slide) (Fig. 56).

After a time we had the pleasure of receiving a growing number of interested visitors. Although at that time we had no television monitor, behind my back there was always a crowd of visitors who were waiting their turn at the microscope tube. Doctor Beekhuis has immortalized a true dialogue of two Italian visitors (slide) (Fig. 57).

After five or six exciting years of hard and inventive work, which resulted in a surgical concept and a combination of vitrectomy, retinal



Fig. 56. A suggestive V.A. check-up

surgery and silicone tamponade for treatment of complicated cases of retinal detachment, I wrote a book in which I tried to explain all this<sup>10</sup>. From the publishing of the work in 1987 until now no new things have occurred with me. Also generally speaking even if we take into account the Phantastic contribution of Stanley Chang (perfluorocarbon heavy liquid used as an instrument for re-attachment of the retina) nothing essential has happened in vitreo-retinal surgery in the last few years. As I have said before, due to the biologic nature of the problem the real breakthroughs need to be expected from parmacological treatment, which unfortunately, does not seem to be very near. In the meantime two things remain: First, to try each time to find a balance between well-considered, aggressive, radical surgery and as atraumatic as possible performance of that surgery, and second, to try to improve the level of con-



ventional and trauma surgery, to improve control and laser treatment of diabetics, because a great number of our cases is still of direct or indirect iatrogenic etiology.

### VIDEO

At the end of my lecture let me answer the question whether I had obstacles on my professional way, particularly concerning my contribution to the development of vitreo-retinal surgery.

My professional career was very unbalanced, characterized by changes of surroundings, hospitals and countries and consequently by compulsory changes of professional activities. In all this, there was little system or school in my education, and the biggest part of it was self-education. What persisted all the time was the interest in surgery and the patient, as well as



constant dissatisfaction with achieved results. At the moment when I achieved results that were relevant and interesting for the others, I had no problems in publishing them and I was immediately accepted. Maybe because the things I discussed were correct and evident, but what is even more important, they came at the right time.

When young people ask me what is needed to become a vitreo-retinal surgeon I usually answer that it is important to work very much and to be persistent-but that is important in any profession. That it is useful to be somewhat neurotic and never to be sure that one has removed the very last membrane, but to keep looking for it again and again. And to be able to bear it all, it is also good to be just a little bit a masochist, but what is most important one has to feel distressed for every eye one has to give up.

Thank you very much for your attention. Finally, I would like to show you a video-film of six or seven minutes about the present possibilities in vitreo-surgery

---

## References

---

1. Cibis P.A., Becker B., Okun E., Canaan S.: The use of liquid silicone in retinal detachment surgery. *Arch. Ophthalmol.*, 68, 590-599, 1962.
2. Cibis P.A.: Vitreous transfer and silicone injections. *Trans. Am. Acad. Ophthalmol.*, 68, 983-987, 1964.
3. Scott J.D.: Treatment of the detached immobile retina. *Trans. Ophthalmol. Soc. U.K.*, 92, 351-357, 1972.
4. Scott J.D.: The treatment of massive vitreous retraction by the separation of pre-retinal membranes using liquid silicone. *Mod. Probl. Ophthalmol.*, Karger, Basel, 15, 285, 1975.
5. Kasner D.: Vitrectomy: A new approach to the management of vitreous. *Highlights Ophthalmol.* 11: 304, 1968.
6. Machemer R.: Vitrectomy, a pars plana approach. By Grune & Stratton Inc., 1975.
7. Machemer R.: Retinotomy. *Am. J. Ophthalmol.* 92, 768-774, 1981.
8. Usui M., Hamazaki S., Takan S., Matsuo H.: A new surgical technique for the treatment of giant tears. Transvitreal fixation. *Jap. J. Ophthalmol.* V., 23, 206-215, 1979.
9. Ando F., Kondo J.: A plastic tack for the treatment of retinal detachment with giant tear. *Am. J. Ophthalmol.*, 95, 260-261, 1983.
10. Zivojnovic R.: Silicone oil in vitreoretinal surgery. Martinus Nijhoff/Dr. W. Junk Publishers, 1987.