

Computer assisted corneal topography in refractive surgery

DRA. CARMEN BARRAQUER C., M.D. *
DRA. ANGELA M. GUTIERREZ M., M.D. *

ABSTRACT

We described the different topographical patterns in spherical and astigmatic refractive defects. Also we analyzed unusual patterns that suggest corneal power eccentricities as a variable of a normal cornea or pathologic cornea.

Topographical analysis of the cornea with the aid of a special computer program. Is a new field of great clinical usefulness for achieving a better understanding of refractive defects, progressive corneal pathology and post-surgical evaluation of any anterior segment surgery.

Several instruments are presently available on the market for this purpose. Our work has been with the "Corneal Modeling System" topographer, which projects an image of 32 concentric ring onto the cornea. These ring images are captured by a digital video system and analyzed. The computer is then fed with information on a surface made up of 8192 data points. This information is processed and analyzed, resulting in a video image of the corneal power distribution in the form of a color topographical map. The warm colors represent high powers while cold colors represent low powers. The program offers other alternatives which are presently being developed, such as laser pachymetry and three-dimensional reconstruction (wire frame) of the corneal structure analyzed.

From the clinical point of view, we have found it very useful in preoperative examination of refractive surgery cases.

In refractive surgery, accuracy of results is presently based on the predictability of the tissue response to the surgical plan.

This paper was presented at The Combined Annual Meeting of the Egyptian Ophthalmological Society and the Saudi Ophthalmological Society in collaboration with The Pan Arab Council of Ophthalmology, Cairo -Feb/90, and at the Third International Symposium of Ocular Microsurgery, Singapore-March/90.

* From the "Instituto Barraquer de América". Bogotá, Colombia.

The cornea is not a perfect lens; its power distribution is unique. Features defining it are: the location of the maximum corneal power, symmetry of power distribution, regularity of the corneal surface and eccentricity of corneal power.

The following corneal patterns have been found through computer assisted topographical studies.

1. Spherical refractive defects, characterized by broad areas of power of uniform and similar refractive value, although there may be small zones that are outside the average.

It is not possible topographically to make a diagnosis of the type of spherical defect; as ametropies of a purely spherical type are rare. In general, axial length is the main cause of ametropias.

2. Astigmatic refractive defects are characterized by the lack of uniformity in corneal power distribution, which is generally expressed with symmetry of power between corneal hemispheres, but with differences between the center and the mid-periphery. The vertical or horizontal direction of corneal power indicates the astigmatic axis. Also it is possible, to found different patterns of astigmatism on normal corneas (Figs. 1-1a).

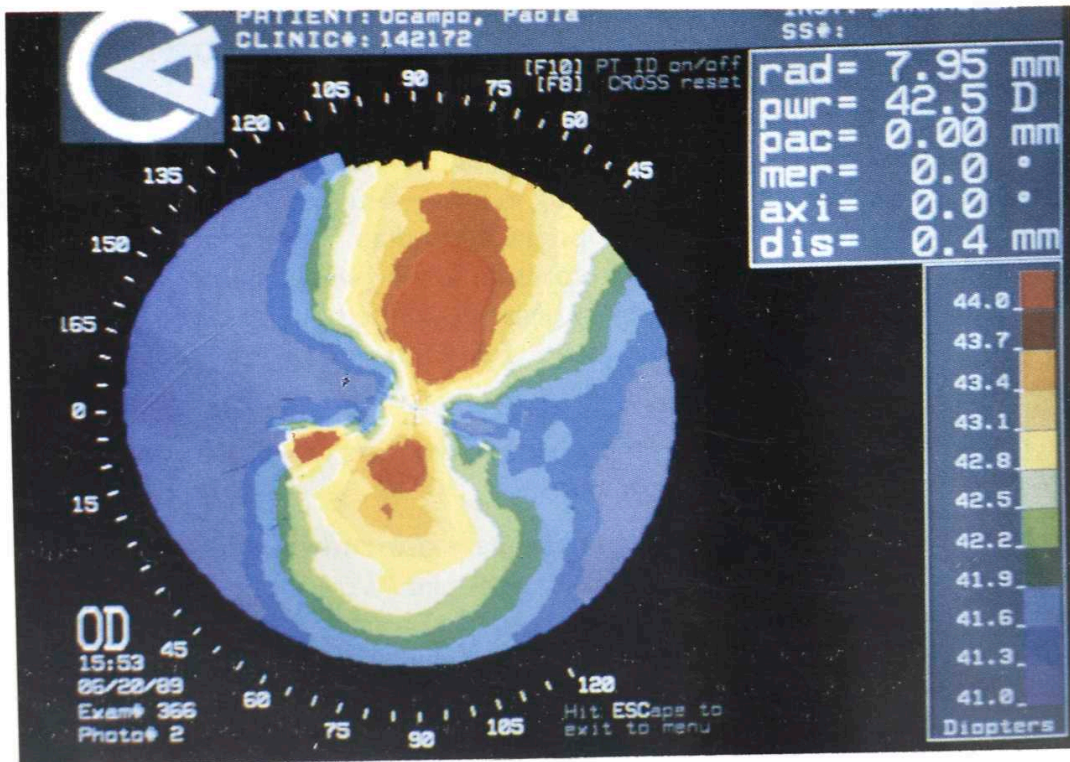


Figure 1. Pattern of with the rule astigmatism.




Figure 1a. Wire frame representation of the astigmatic defect with the rule.

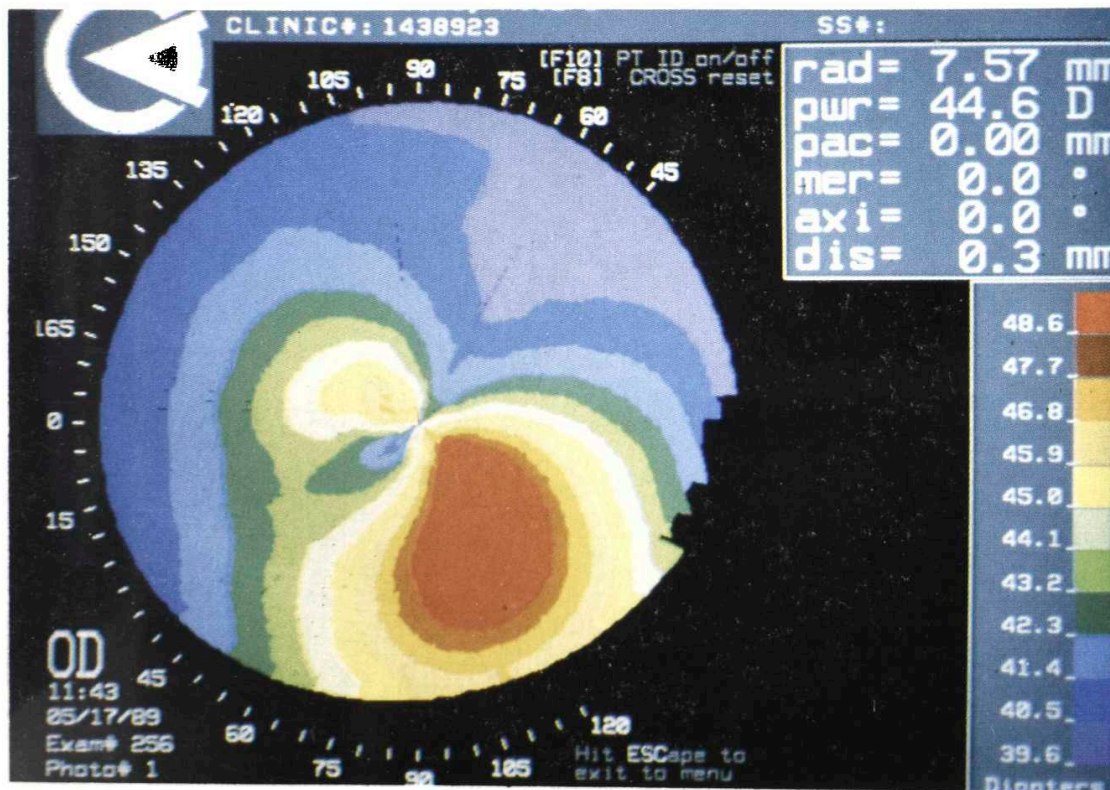


Figure 2. Topography of a keratoconus with eccentricity and asymmetry of corneal power.

Corneal power may subsequently be located in the center of the visual axis or distributed symmetrically between the two hemispheres in normal corneas.

DISCUSSION

It is well known that ECTASIAS, Whether the corneal pathology is primary or secondary in nature, are characterized topographically by the eccentricity they generate in the corneal power (Fig. 2).

In primary ectasias most corneas are classified as Keratoconus, Keratotorus and other anomalies that are the expression of molecular disturbances of the corneal collagen, wich alter its structural behavior in a way that we are not able to predict.

Secondary ectasias, are the normal response of a cornea that has been sectorially weakened in its structure (Figs. 3-3a). This change can be measured and predicted consistently, with the individual characteristics of each case.

Because of its clinical-diagnostic importance, we have been struck by the finding of otherwise normal but asymmetrical corneas, characterized by eccentricity of power in different locations. None of these patients had used contact

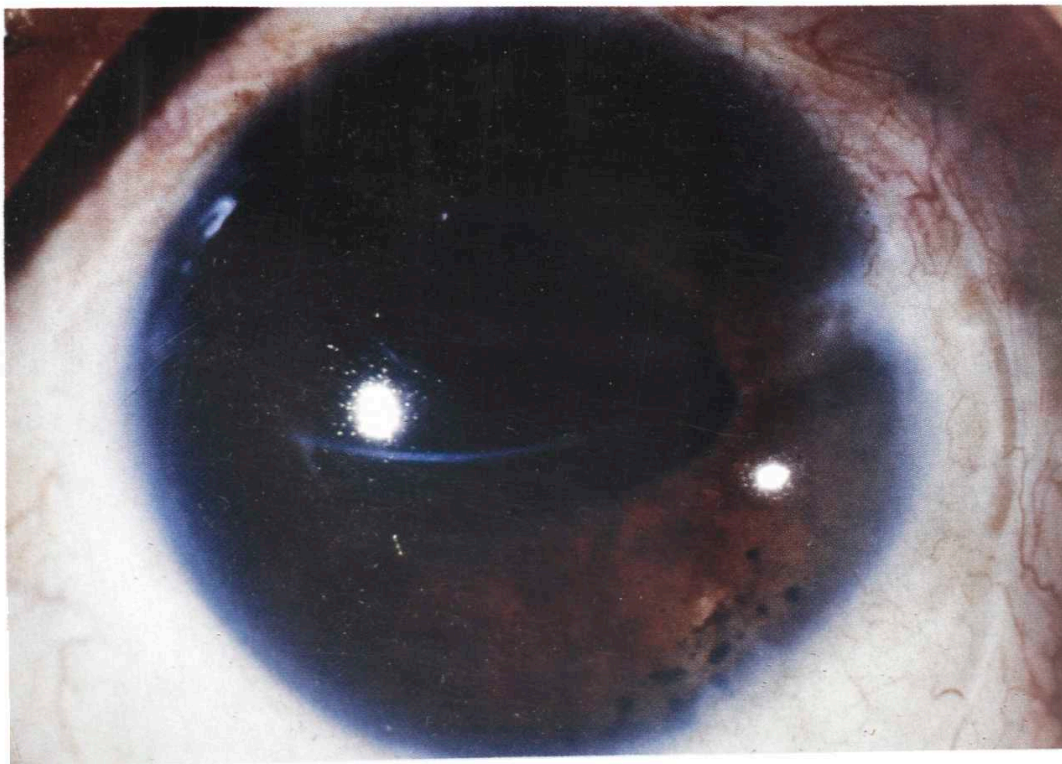


Figure 3. Corneal leucoma secondary to a penetrating wound.

lenses for the last 30 days. Generally in this cases, the eccentric power does not exceed more than 3 diopters the average of the corneal power.

The question arosed was: Are these corneas subclinical ectasias or simple variations of normality?

In refractive surgery, accuracy of results is presently based on the predictability of the tissue response to the surgical plan.

We therefore consider that all corneas showing primary power eccentricity, whatever their location, should be excluded from the usual refractive surgical techniques and carefully analyzed before making surgical decisions for correction of ametropia.

We present one clinical case as an example of a normal cornea with power eccentricity and its surgical response (Fig. 4).

After a careful analysis of this case, and being sure that there was not a primary ectasia, we assumed that eccentricity of power at 6 o'clock was already a knee, and we decided to perform a radial keratotomy with only 7 incisions. (Fig. 4a.)

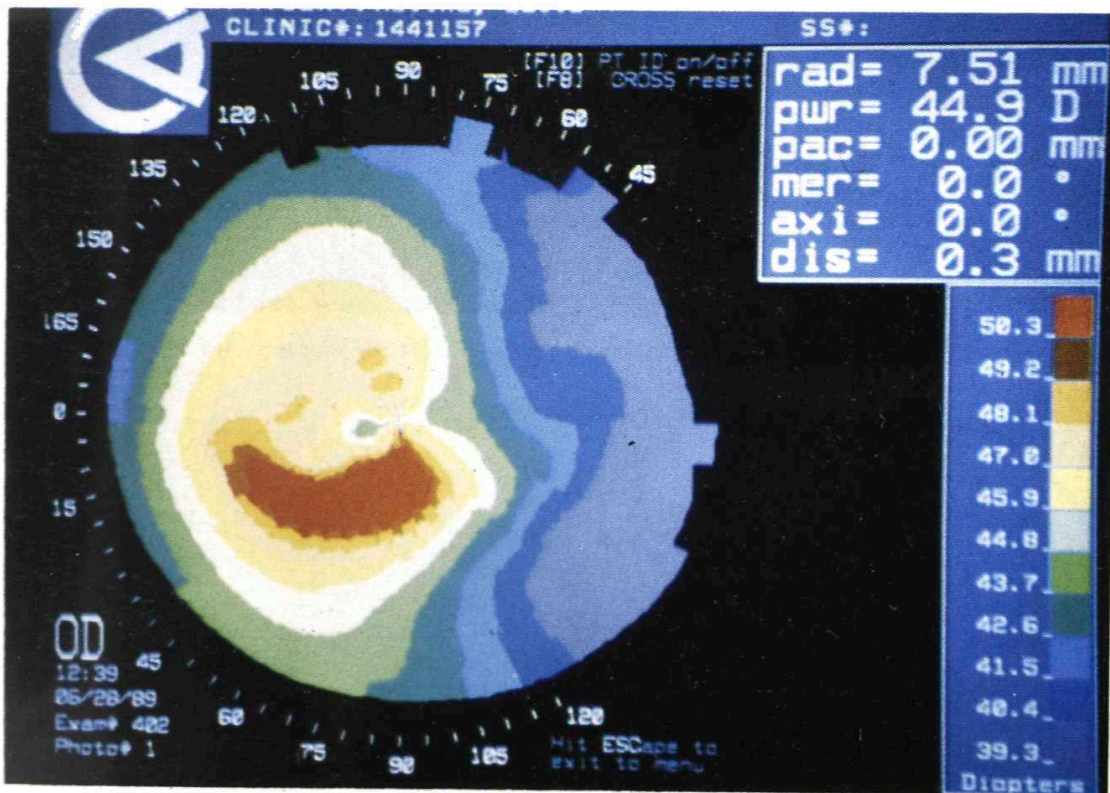

Figure 3a. Topography of the same cornea showing eccentricity of power.

The result of the surgery shows a very good central flattening with a simetrical surrounding ring of steepening that is the normal shape of a radial keratotomy topography. (Fig. 4b).

In conclusion, corneas must be carefully examined before surgery to avoid performing refractive surgery in corneal ectasias. Power eccentricities should be handled as unique cases, designing techniques for each of them according to the actual knowledge of the tissue response in the specific case.

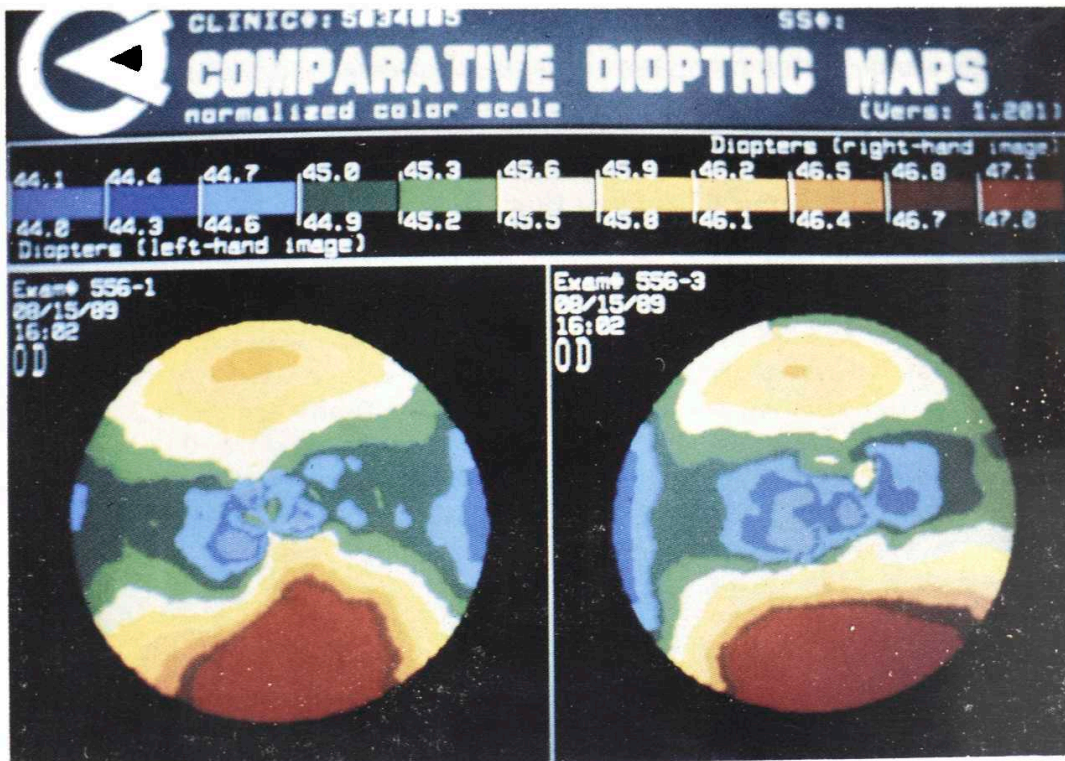


Figure 4. Preoperative topography of a myopic patient with 40 diopters and inferior corneal power eccentricity.

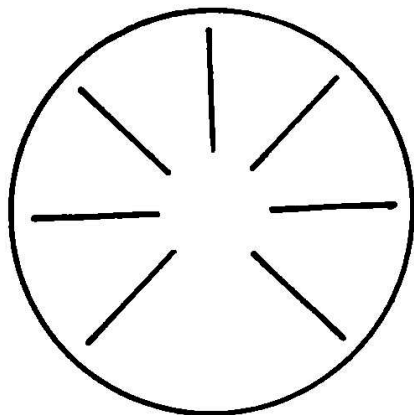


Figure 4a. Surgical schema with 7 incisions.

COMPUTER ASSISTED CORNEAL TOPOGRAPHY IN REFRACTIVE SURGERY

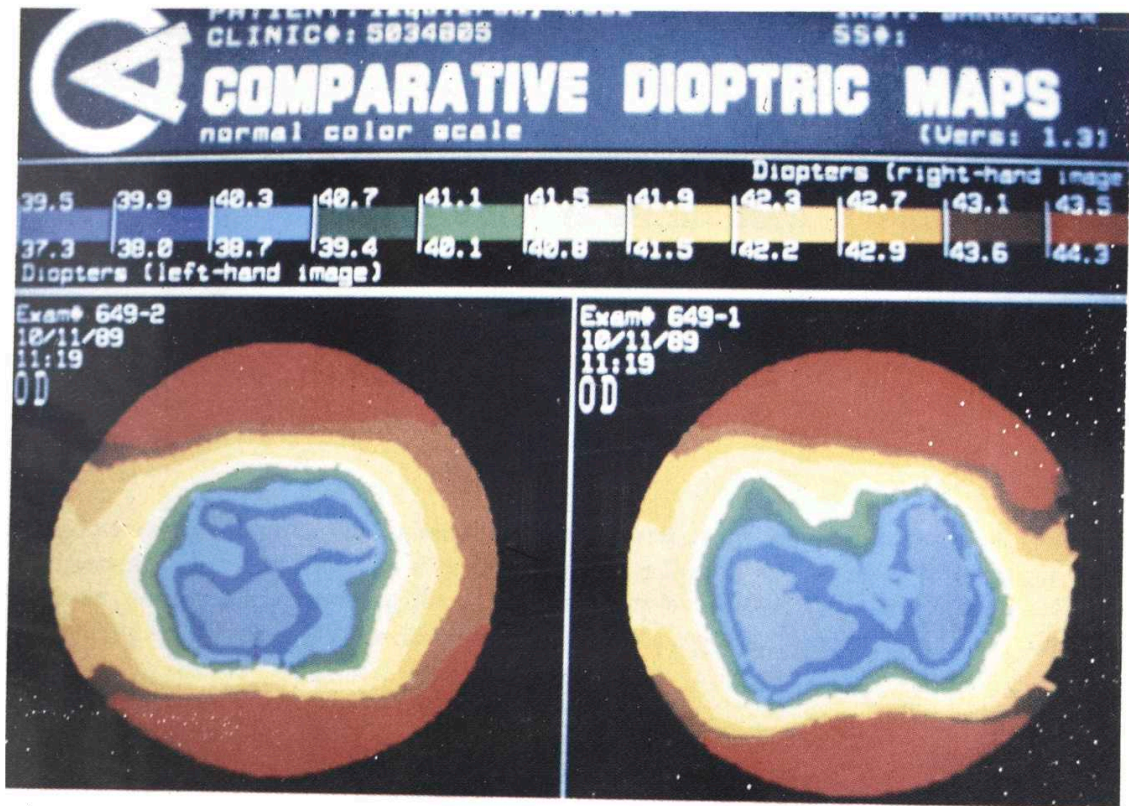


Figure 4b. Postoperative radial keratotomy topography with central and uniform flattening.