

## PERSONAL EXPERIENCES WITH THE USE OF ALPHA-CHYMOTRYPSIN

BY

R. M. FASANELLA, M. D.

New Haven, U. S. A.

Above a picture of the world in the Air Travel Bureau in Barcelona, one can find the following words: "At first it was thought this was the end of the world. Now it has been found only to be the starting point." (This is a free English Translation, of course).

It seems rather fitting that Barcelona should be the starting point for another exploration. This time, some centuries later, the Barraquers started their pioneer work on the use of Alpha-Chymotrypsin in cataract surgery. As you know, Alpha-Chymotrypsin is a proteolytic enzyme obtained from mammalian pancreas.

You may recall that others used the trypsin in the eye in an attempt to dissolve blood and vitreous opacities. Some abandoned its use because the lens was noted to be dislocated.

It was Joaquin Barraquer a who was keen enough to foresee the potential good of what seemed at the time to be a major complication. One day, after an attempt to dissolve a large vitreous opacity with trypsin, he noted that the lens had become dislocated. At this point, instead of abaddoning the use of the drug as harmful, Dr. Barraquer set up a series of animal experiments to determine a safe concentration of Alpha-Chymotrypsin for chemical zonulysis. This substance, when injected into the anterior chamber of the human eye, seemed to have a selective lytic action on the zonule and, in the proper concentration, respected the remaining intraocular structures. This new adjunct seemed to open a new surgical field substituting a mechanical zonulotomy technique, employed up until this time, by a chemical one.

Ideally, in the beginning it was felt that:

1. Intracapsular extractions would be possible at any age.
2. Extracapsulars would be unnecessary and in consequence, the inherent complications of an extracapsular would be lessened, such as;
  - a. secondary cataract
  - b. iridocapsular synechias, and

c. accidents occurring during and after intracapsular extractions would be minimized or eliminated such as;

- a. tearing of the capsule
- b. iridocyclitis secondary to excessive traction
- c. loss of vitreous humor secondary to excessive traction or pressure and
- d. retinal detachment due to excessive traction or pressure.

As in all new work, sometimes the ideal cannot be achieved at first or at any time.

It is the purpose of my paper to review briefly the first fifty cases of cataract extraction, using Alpha-Chymotrypsin, that I have personally performed and analyzed.

I shall also comment on other difficult cases done at New Haven Hospital that I have personally observed.

My objective in this study was to try to determine the indications for the use of Alpha-Chymotrypsin, its contraindications, the pitfalls, complications in its use and the management of these complications. In a sense, this study might be compared to the work of an engineer on studies of metal tolerances.

I shall also try to point out in my comments how and where I think Alpha-Chymotrypsin works, what studies are now being done, and what may be the future trends in its use.

It must be pointed out that my thoughts and ideas have been flexible and changable as I have talked and written to colleagues. I am deeply indebted to the Barraquers whose clinic I visited and with whom I have interchanged many letters as problems presented.

I would like to express my gratitude also to Drs. Richard Troutman, (3) Robert Bedrissian, (4) Morgan Raiford (5) and Hervery Thorpe (6) along with many others for their thoughts and interchange of ideas.

The following plates summarize my personal experiences in the first fifty clinical cases in which I used Alpha-Chymotrypsin.

#### SUMMARY OF USE OF ALPHA - CHYMOTRYPSIN IN 50 CLINICAL CASES

AGE GROUPS	RACE AND SEX
80—89=90	Race — All White
70—79=13	Sex — Males 23
60—69=15	Females 27
50—59= 5	(Oldest — 88)
40—49= 5	(Youngest — 11)
10—39= 3	

Fig. 1

ALPHA - CHYMOTRYPSIN

CATARACT TYPES

ADULT

<i>Senile</i>	<i>Traumatic</i>
Mature — 27	Mature — 2
Immature — 17	Immature — 1
CONGENITAL	
Mature — 1	
Immature — 2	

Fig. 2

COMPLICATIONS — PREOPERATIVE

SYSTEMIC (SEVERE)	LOCAL
Allergy — 4	Glaucoma — 4 (2 secondary)
Hypertension — 6	Corneal Scars — 3
Diabetes — 7	Myopia (high) — 3

Fig. 3

ANESTHESIA

GENERAL .....	7
LOCAL .....	43
LOCAL AND INTRAVENOUS .....	7
(ANESTHESIA INADEQUATE IN 5 CASES)	

Fig. 4

ALPHA - CHYMOTRYPSIN (ALL PEVYA) (3 BATCHES)

DILUTION	AMOUNT
1/5000 in 46 cases	1 cc. to 5 cc. (Average 1 to 2 cc.)
1/2500 in 4 cases	

TIME IN SOLUTION BEFORE USING — 1 to 3 hours

TIME IN ANTERIOR CHAMBER BEFORE LAVAGE — Average 3 minutes

ADDITIONAL ALPHA - CHYMOTRYPSIN — 4 cases

Fig. 5

*OPERATIVE TECHNIQUE**INSTRUMENTS*

Keratome and Scissors	47
Graefe Knife and Scissors	2
Scratch (2 keratomes were no good)	1

*SUTURES*

Chromic (2 was least number-average 5)	45
Silk (8 was largest number-average 5)	5

*FLAP*

Limbal in each case

*EXTRACTION*

Intracapsular (2 started as extra-)	48
Extracapsular	2

Fig. 6

*POST - OPERATIVE MEDICATION*

Pilocarpine	17
Atropine	13
Nothing	19
Unlisted	1

Fig. 8

*COMPLICATIONS**OPERATIVE*

Loss of Formed Vitreous	1
Presentation of Formed Vitreous With no Loss (Vitreous Lens Adhesion)	8
Pigment Loss	8

*POST OPERATIVE (IMMEDIATE)*

Hyphemia	5
Absent Shallow Anterior Chamber	4
Iris Prolapse	2

*POST - OPERATIVE (LATE)*

Wound Disruption (5 weeks post-op)	1
Detachments (1 month post-op)	1

Fig. 9

## FACILITY OF CATARACT EXTRACTION

---

Easier . . . . .	31
Not Easier . . . . .	12
Questionable . . . . .	7

---

Fig. 10\*

\* In many cases I had to use the erisophake to slow down and brake the delivery of the lens which presented rapidly. In a sense one is handling a "greased pig" or operating on more dislocated lenses. Fortunately, however, at the time most vitreous faces are intact.

## OPERATIVE TECHNIQUE - PRESENT

- 
1. Corneo-scleral incision with fornix based flap.
  2. Post placed sutures.
  3. Alpha-Chymotrypsin (1/5000)  
(Injected below usually).
  4. Wait 3 minutes.
  5. Iridectomy or iridotomy.
  6. Erisophake filled with saline.
  7. New washing (optional).
- 

Fig. 11

## SUMMARY AND SOME CONCLUSIONS OF MY OWN FIFTY CASES

Clinically, in these fifty cases performed by me, I have lost *formed* vitreous once. This one seemed related to lens vitreous adhesions and poor anesthesia. In addition, in this case, despite the seven sutures, I had an iris prolapse.

## WOUND SEPARATION

I have had one wound separation in a child of ten years of age. This child was diagnosed as having subnormal development as well as retrolental fibroplasia and nystagmus. The patient who was living in an Institution at the time, fought her eye medications and it is possible that trauma, rather than the Alpha-Chymotrypsin, caused the wound to become disrupted. The wound separation occurred approximately five weeks post-surgery. Discounting this case of late wound separation, I have had two iris prolapses, both of which were noted and repaired one day postoperatively. One of these cases had only two chromic sutures. In this patient, I used only two sutures because the patient was unusually cooperative and because the corneal incision and closure seemed so perfect.

In a letter from Joaquin Barraquer, he told me that he had a recent series in which he had wound separation at approximately the two-week period. Therefore, he was washing out the Alpha-Chymotrypsin more carefully and using more of the 7-0 silk sutures.

#### PIGMENTATION (EXCESSIVE)

On injection of the Alpha-Chymotrypsin with one particular bath of the Barraquer solution, I noted more pigmentation resembling that seen in operating on diabetics.

I noted less when I irrigated in only one site under the iris rather than four sites as I had done to this point. After I received a fresh bath of Alpha-Chymotrypsin, I noted even less pigmentation. No excessive pigmentation was noted in the four cases in which Alpha-Chymotrypsin was diluted to 1/2500. Therefore, I concluded that the mechanical processes an/or the standarization of the Alpha-Chymotrypsin might have been at fault. Clinically speaking again, I have seen no real iris atrophy as I would expect with loss of pigment. In this respect, I wondered how much of a part the irrigation and irritation of normal saline may have had the chemical contact and recontact of the iris by the needle used in inserting the Alpha-Chymotrypsin may play a part in this loss of pigment. These contacts therefore should be kept to a minimum.

#### RETINAL SEPARATION

To date there has been only one case of postoperative retinal separation in a patient in whom I used Alpha-Chymotrypsin. This patient had a mature cataract with a controlled closed angle glaucoma. I performed an uncomplicated intracapsular extraction with a broad basilar iridectomy. In this case there seemed to be no relationship to the use of Alpha-Chymotrypsin. There was no loss of vitreous or vitreous presentation. There seems to be a disagreement as to whether Alpha-Chymotrypsin will cause or lessen detachments.

I have looked for damage to the vitreous face, ciliary body and retina but have not been able to see any to date. Indirectly, I learned from Dr. Maumenee (7) that in the rabbit injected with Alpha-Chymotrypsin which has not had the solution washed out, some may have worked its way back to the retina damaging it.

#### ALLERGIC REACTIONS

I feel that I have to watch round pupils after the use of Alpha-Chymotrypsin somewhat more than those in which I have not used Alpha-Chymotrypsin. The



## ALPHA - CHYMOTRYPSIN

pupils seem more sluggish, but this could possibly be related to the trauma of the injection of the Alpha-Chymotrypsin and washing it out. Those eyes in which I used Alpha-Chymotrypsin seemed to stay a little redder than those without.

Personally, I have noted no allergic type reaction in the eyes where I used Alpha-Chymotrypsin a second time or in eyes showing allergies to other drugs.

For example I had a thirty-two year old white male with marked local eye allergies, preoperatively but did not show any increased eye allergy following the use of Alpha-Chymotrypsin.

### EFFECT ON SUTURE MATERIAL

Alpha-Chymotrypsin has no effects in chromic suture material.

### EFFECT ON CORNEA

Alpha-Chymotrypsin did not reactivate an interstitial keratitis with active "ghost vessels" nor did it reactivate several scarred corneas. Although I used Alpha-Chymotrypsin on the eyes with preoperative corneal scarring, I avoided its use in four eyes that I had performed corneal transplants. In all four, intracapsulars were obtained *without* the use of Alpha-Chymotrypsin. The corneas remained clear.

### EFFECT ON EXTRACAPSULARS

In two extracapsulars, which started as intracapsulars, it was possible to wash out the capsule almost in one piece. It was felt that Alpha-Chymotrypsin may have dissolved the zonules thus making the remaining capsule wash out somewhat easier.

### SOME POSSIBLE INDICATIONS

At present, I personally do not feel that Alpha-Chymotrypsin should be used in patients under twenty years of age or in those patients sixty years or over. Alpha-Chymotrypsin has been of definite help to me in the twenty to forty age group. In the younger age group, the greater danger of vitreous loss is a deterring factor. This may partially be explained by the higher frequency of lens vitreous adhesions. In most patients, after sixty, unless the cataract is predominantly nuclear, I feel that Alpha-Chymotrypsin is of no benefit and may even cause a fragile capsule to rupture more easily because of the extra manipulation. However, Thorpe felt just the opposite in regard to mature cataracts. He felt there was a greater chance to obtain more intracapsulars with Alpha-Chymotrypsin.

In the intumescent cataract, I personally feel that the capsule and zonules are so weak that Alpha-Chymotrypsin is indicated in most cases of anterior and posterior polar, complicated (posterior cortical) and nuclear cataracts.

I personally favor the use of Alpha-Chymotrypsin in high myopes and those with potential or previous detachments. Many will disagree with me on this, I am sure.

For those who prefer sliding, selective insertion of Alpha-Chymotrypsin at the 12 o'clock position with the head inclined slightly backward so that the Alpha-Chymotrypsin can reach this area and stay in this area may facilitate the extraction. The head, of course, should be level during the actual extraction.

Selective sliding or tumbling may be facilitated by the selective injection of Alpha-Chymotrypsin in other areas.

In one case in which the selective sliding should have worked, it failed.

Alpha-Chymotrypsin should be fresh and not inactivated by heat such as probably occurred in one case in which a substitute nurse placed the enzyme in a hot autoclave unbeknown to me. It did not work in this case of course.

#### DIFFICULT CASES I PERSONALLY OBSERVED

Except for the first case, I shall describe briefly only the more unusual cases.

Alpha-Chymotrypsin was first used in New Haven Hospital in May, 1958 on a twenty-six years old male patient. This Alpha-Chymotrypsin was sent to me by the Barraquers. The operation was witnessed by many, all of whom felt that it was one of the most exciting events in many years in the field of ophthalmology. The operator feared that the lens might dislocate posteriorly; actually, the Bell erisophake was applied only once and with a tumbling maneuver the lens was delivered without incidence. The Alpha-Chymotrypsin was instilled thru the iridectomies as was originally recommended by the Barraquers. At that time it had been feared that the Alpha-Chymotrypsin might create poor wound healing or might destroy chromic sutures used in cataract surgery. Since then, however, our own studies with chromic sutures and Alpha-Chymotrypsin show no changes of the suture material. This was confirmed by experimental work of others.

The second case which I observed was that of a thirty year old white male with a congenitally dislocated lens. The patient has asthma and a high myopia. My colleague felt that this case was not a Marfans but that the remaining zonules would be resistant. Therefore, he felt that Alpha-Chymotrypsin might aid in the extraction of the lens. Alpha-Chymotrypsin did not seem to help. Vitreous was present and some was lost. More work with Alpha-Chymotrypsin in ectopia lentis may be indicated.



## ATOPIC DERMATITIS

In a patient twenty years of age with atopic dermatitis and a mature lens, Alpha-Chymotrypsin did not help. Vitreous was lost and a flat chamber followed. Technical problems unrelated to the Alpha-Chymotrypsin were probably responsible. Fortunately, however, the final postoperative vision with correction was 20/30+4.

## AGE GROUP 0 TO TEN

In a four-year old operated on by an excellent surgeon with a good assistant, the Alpha-Chymotrypsin was repeated and the zonules had to be stripped manually and vitreous was lost. Possible causes of failure here were vitreous lens adhesions and lack of freshness of the Alpha-Chymotrypsin (four hours or more old).

In a five-years old with a clinical diagnosis of mongolian idiocy, Alpha-Chymotrypsin seemed most helpful in performing an intracapsular extraction combined with a total iridectomy. However, when the second eye was operated on by the same team of surgeons, vitreous was lost. A vitreous lens adhesion seemed responsible in the case of the second eye. It is difficult to explain why in one eye there seemed to be a vitreous adhesion while in the other there was apparently none.

## FINAL DISCUSSION AND CONCLUSIONS

The work of Bedrossian suggest that the enzyme softens or weakens the zonule without actually dissolving it.

Dr. Leon Stone of Yale, in a personal discussion, of the mechanism of the trypsin felt that the effect of these enzymes in correct concentration might be on the intercellular cement substance without dissolving the cells themselves. Over-simplifying this conception, we might consider the effect of a chemical agent attacking the cement holding bricks together but not destroying the bricks themselves. Barraquer and Bedrossian separately reported no microscopic changes in other structures of the eye. Bedrossian, however, concluded that although no microscopic changes were seen in other structures, they might be affected as in the zonules and still show no pathologic changes.

I could not find any details on the chemistry of the zonules. Examining the intracapsular lenses under the biomicroscope postoperatively, I noted no attachment of the zonules to the lens. This suggested to me that perhaps the weakest point might be at the insertion of the zonules to the lens proper. Franceschetti (8) feels this is the site of action. As yet, our pathologist has been

unable to help me on this point. As you may know, there are often detachments of the zonular lamella secondary to technical difficulties in preparing slides of the capsule and zonules.

Following the suggestion of Thorpe, I examined as many eyes as I could with the gonioscope and I felt that the break may have occurred in this place. However, in a few cases the break seemed to occur at the ciliary processes. Others have reported that in normal intracapsular extractions, usually the break is at the mid-point of the zonules. Some feel the mid-point is also where Alpha-Chymotrypsin works.

Bedrossian in careful studies on animal eyes concluded that corneal wounds are not affected when they are bathed in 1:5000 solution of the enzyme for thirty minutes nor was wound strength diminished after fourteen days (9).

However, when I told him about the excess pigmentation I was encountering and the one delayed wound rupture I had, Joaquin Barraquer wrote the following in December, 1958:

"I have not observed any loss of iris pigment and I should think it might indeed be a mechanical problem, just as you yourself suppose.

I have seen more cases of late loss of the anterior chamber lately, usually, ten or twelve days after operation. This might be due to a delay in cicatrization, but I am not sure about it and I am now trying to find its cause.

In so far as congenital cataracts are concerned, I had excellent results in my first series of April, May and June of 1958. There were round pupils and showed no greater difficulties than in older people.

My second series as you saw yourself presented difficulties with vitreous herniation. The third series in November was made with total iridectomies and the vitreous showed a greater tendency to prolapse. I do not understand this difference between my first case and the others. Perhaps it is due to a difference in the enzyme."

Dr. Barraquer concluded in his letter, "For the time being, I advise the use of the enzyme only in patients from *ten* to *fifty* or *sixty* years of age. In other words, I would not advise its use in small children or in old people."

There has been a loss of vitreous in 100% of the cases of operations on children under the age of ten using Alpha-Chymotrypsin. Dr. Paufigue (10) reported he had three cases, Dr. Franceschetti (11) two cases and Dr. Boyd (12) two cases. I do not know many cases Dr. Cogan has had of this type but he described operating on a child under the age of ten using Alpha-Chymotrypsin as "extreme suffering." (13)

## BARRAQUER'S CONCLUSIONS

March-1959

In March, 1959, Dr. Barraquer wrote me the following: "As far as cicatrization of the incision is concerned, I think that Alpha-Chymotrypsin actually does produce a bit of delay (a certain subconjunctival filtration is seen more frequently). This delay is of no clinical consequence if the suturing is done carefully. The incision should be closed in two planes (with limbus based flaps or with fornix based flaps) and all the stitches should be covered by conjunctiva. It is advisable to use natural silk. It is essential to wash the incision well with saline solution after having applied Alpha-Chymotrypsin in the posterior chamber."

Dr. Barraquer continued, "with regards to the use of the enzyme in young patients, my experiences lead me to the following conclusions:

1. Alpha-Chymotrypsin produces a lysis of the zonules which is similar to that in older people.

2. The problem in the young is due to the tendency of vitreous to prolapse probably because the sclera is more elastic and compresses the vitreous humor when the anterior chamber is opened.

3. Zonulolysis should *not* be employed in children under ten years of age, except in experimental cases and in specialized centers in order to study attempt to overcome this complication. This, of course, only in blind eyes (i.e. in unilateral cataracts with irreversible amblyopia).

4. In the age group between ten and twenty, a skilled surgeon may employ the enzyme provided he has a good anesthesia and hypotony.

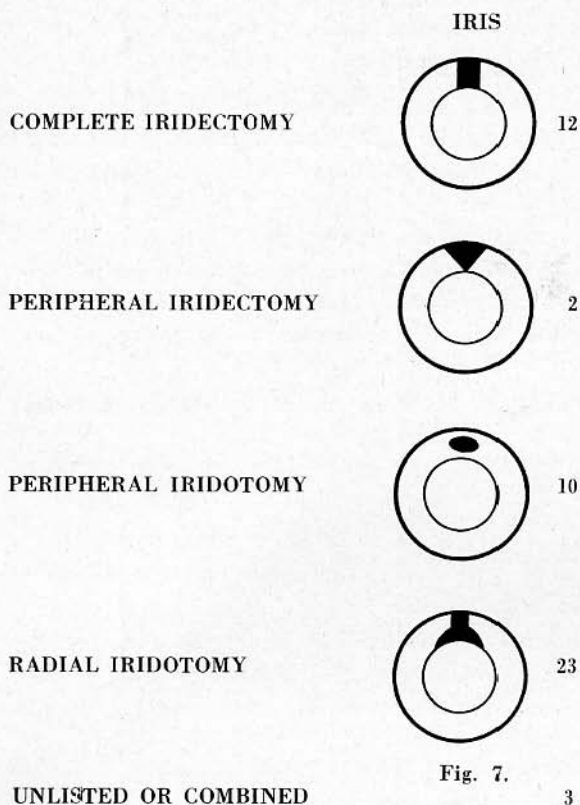
5. From the age of twenty onwards, I have not had any more difficulties than with senile cataracts except on rare occasions (some myopes).

6. The Alpha-Chymotrypsin must be freshly prepared in individual vials.

At present, I prefer to dilate the pupil with Neo-synephrine to about 8 mm., for sometimes washing the enzyme behind the iris contracts the pupil further. I am still using a 1:5000 solution. Higher dilutions have often proved ineffective. I think the suction cup is most ideal".

## FUTURE TRENDS AND STUDIES

As you know, the Rockefellers have given many millions of dollars to charity and to investigative research. It is said that the best \$ 5,000 they ever gave was that given to Dr. Fleming who discovered penicillin. As you know, research and discovery of many other antibiotics blossomed from this "accidental discovery" by a man who had eyes to see. Today there are many new antibiotics. Likewise, there are many other enzyme preparations like Alpha-Chymotrypsin that remain



to be investigated. At our institution some of this work has already begun. The exact chemistry of the zonules, the lens capsule and the exact mode of action of drugs like Alpha-Chymotrypsin is still to be solved. We are all indebted to the Barraquers for all they have done toward the goal of making cataract surgery safer.

One day, it is hoped, "we will need speak no longer of management of eye surgery, but only of avoidance of pitfalls."

842 Howard Ave.

#### BIBLIOGRAPHY

1. VON SALLMAN, L., In discussion by Troutman, R. C.: "Alpha-Chymotrypsin", Manhattan Eye Ear and Throat Hospital, Eye Staff Conference, December 15, 1958.
2. BARRAQUER, J., Personal Communication.
3. TROUTMAN, R. C., Personal Communication.
4. BEDROSSIAN, R. B., Personal Communication.
5. RAIFORD, MORGAN, Personal Communication.
6. THORPE, HARVEY, Personal Communication.
7. MAUMENEE, A. E., Personal Communication.
8. FRANCESCHETTI, A., From: "Enzymatic Zonulolysis", *Highlights of Ophthalmology*, Vol. 3, n. 1, 1959.