

THE MANAGEMENT OF VITREO-RETINAL DETACHMENT IN DIABETIC RETINOPATHY

Dr. ROLL K. BLANCH*

Londres, Inglaterra

Retinal detachment as a complication of diabetic retinopathy has a different aetiology and a different natural history from simple retinal detachment. Aetiologically, the important factors are the contraction of the vitreous body, the nature of the vitreo-retinal adhesions and the effect of fibrous retinitis proliferans upon the retina.

Vitreous contraction or detachment, which is peculiar to diabetic retinopathy, was clearly described by Hruby¹ who distinguished it from vitreous collapse as occurs in myopia and senility. Hruby's work was elaborated by Tolentino² and given authority by Davis³. Unlike the collapsed vitreous, the detached or contracted vitreous in diabetes maintains its structure and existing areas of vitreo-retinal adhesion may be pulled forward by the contracting vitreous. Thus, on occasion, an operculum may seem to be pulled forward out of the retina leaving a retinal hole, which in turn may be a precursor to a retinal detachment.

It is, however, not uncommon in diabetes to have traction retinal detachment without a retinal hole, whereby the retina is drawn forward by the vitreous at the side of the vitreo-retinal adhesion. Davis³ believes that new vessels on the retina are drawn forward by the contracting vitreous in a similar manner, although once the vitreous itself is detached, it is of course possible that the vessels grow forward towards its posterior surface, the vessels not entering the vitreous gel itself. Fibro-vascular proliferations may thus grow along the posterior border of the vitreous, giving rise to the

* R. K. BLACH, MOORFIELDS EYE HOSPITAL, LONDON.

ROLL K. BLANCH

posterior vitreous membrane. Fibrous retinitis proliferans may develop along the retinal surface itself, and stretch from one part of the retina to another, which, on contraction, can give rise to a particularly difficult type of traction retinal detachment. Where fibro-vascular tissue arises from the disc, the retina around the disc may be dragged forward, giving rise to traction retinal detachment centred upon the disc. It is a feature of traction detachments, as opposed to rhegmatogenous detachment, that they are only very slowly progressive⁴. (Fig. 1).

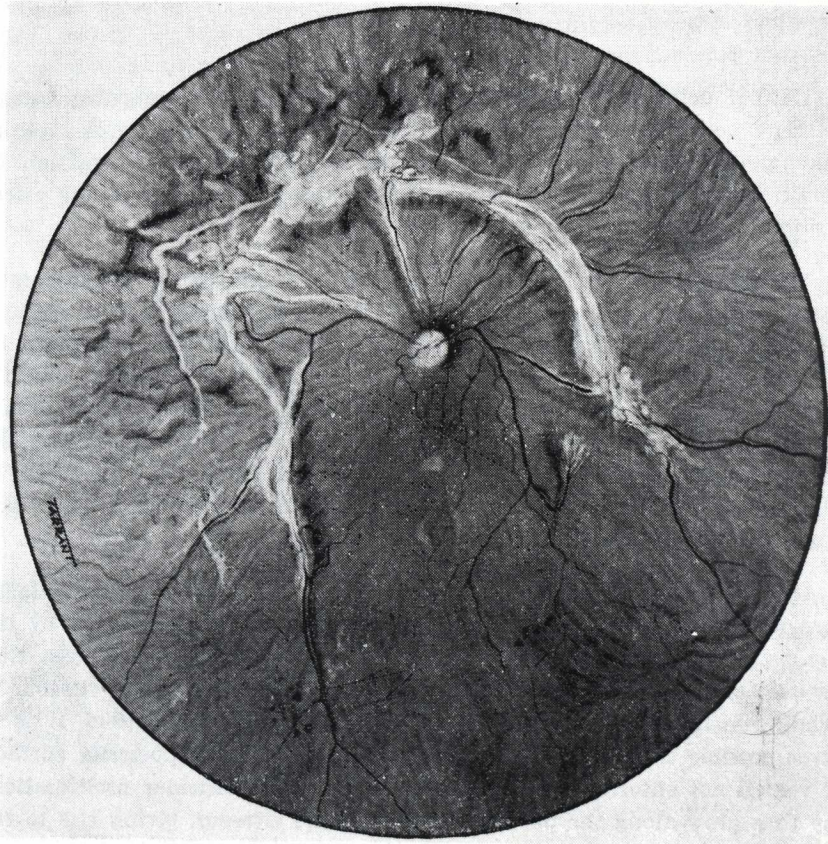


FIGURE 1

Proliferative diabetic retinopathy showing areas of traction detachment.

THE MANAGEMENT OF VITREO-RETINAL

It is seen therefore that the aetiology of diabetic retinal detachment is more complex and its natural history is different from simple retinal detachment and, in deciding how diabetic retinal detachment should be treated, it is important to appreciate the mechanism of detachment in each individual case. Let us therefore consider the different stages and development of retinal detachment in diabetic retinopathy and discuss the management of each stage.

1. *Vitreous Contraction in the Absence of Retinal Detachment*

No treatment is required at this stage. Whether prophylactic vitrectomy or vitreous relieving procedures as suggested by Scott⁵ should be undertaken, is a moot point.

2. *Vitreous Contraction With an Operculum or Retinal Hole in the Absence of Retinal Detachment*

This condition may be accompanied by traction upon the retinal vein. It is desirable to treat the retinal hole by photocoagulation. It has been suggested the two ends of the updrawn vein should be anchored by photocoagulation.

3. *Retinal Detachment in the Presence of a Retinal Hole*

These cases should basically be treated as simple retinal detachments, possibly with the addition of an encircling procedure and removal of sub-retinal fluid in order to relieve the vitreous traction, if this is an important feature.

4. *Traction Retinal Detachment Without a Retinal Hole Where the Macula is Not Involved*

These detachments are best left untreated, as they are only slowly progressive and the detachment procedure itself is not without risk.

5. *Non-Rhegmatogenous Retinal Detachments Where the Macula is Involved*

These cases should be treated by an encircling silicone strap with evacuation of sub-retinal fluid, taking care not to lower the intra-ocular pressure appreciably during this procedure, so as to avoid the risk of haemorrhage from new vessels. This is done by mainta-

ROLL K. BLANCH

ining pressure of the eye as the sub-retinal fluid is evacuated and injecting air into the eye so as to maintain the intra-ocular pressure. Cryotherapy should be applied to areas of neovascularisation. (Fig. 2).

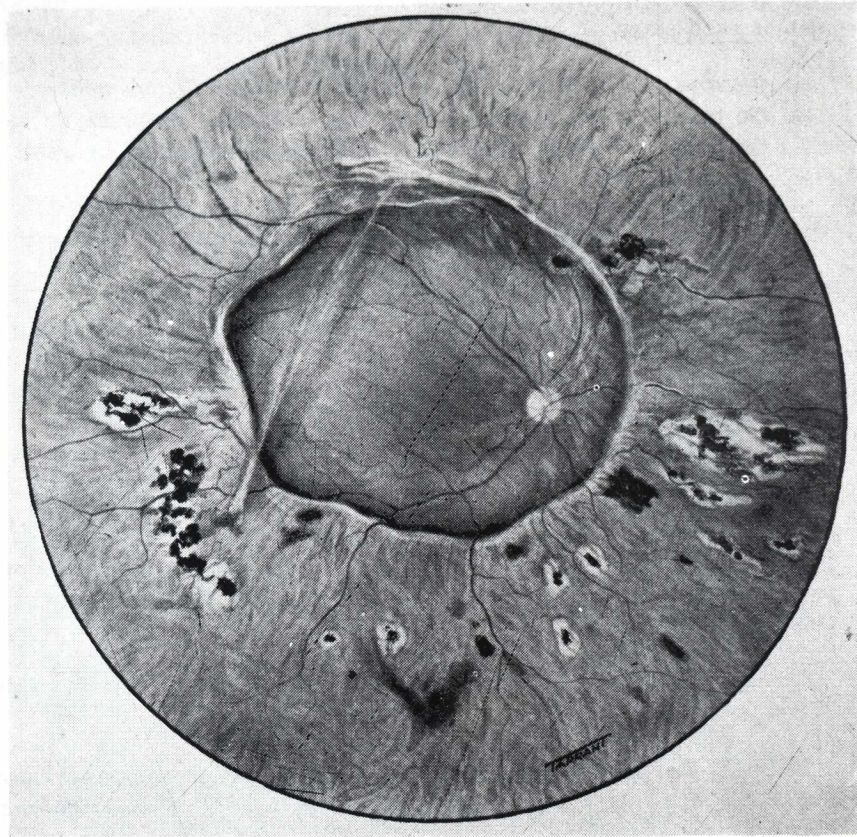


FIGURE 2

Diabetic retinal detachment treated by circlage and cryotherapy. Note vitreous band.

6. *Neovascularisation Without Retinal Detachment*

In these cases the proliferative diabetic retinopathy should be treated on its merits. However, photocoagulation to areas of early fibrous retinitis proliferans might increase the danger of retinal

THE MANAGEMENT OF VITREO-RETINAL

traction since photocoagulation itself can cause further traction to such fibrous tissue.

7. *Vitreous Haemorrhage*

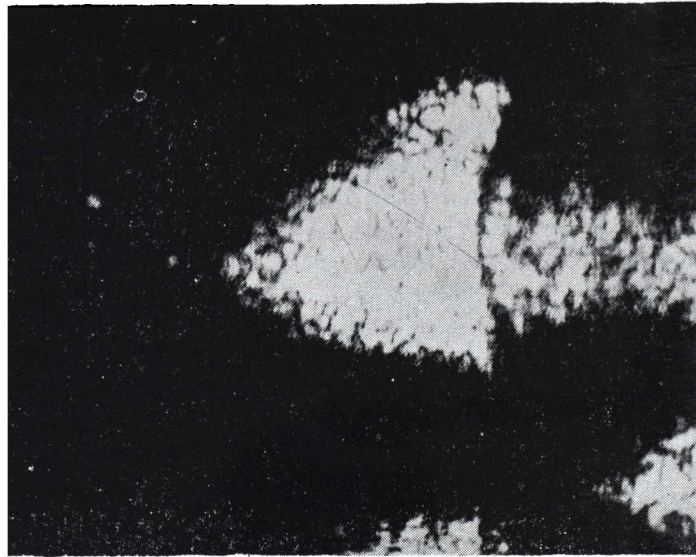
Vitreous haemorrhage is a common and recurring symptom of patients with proliferative diabetic retinopathy. It is frightening to the patient; even when the haemorrhage has cleared, the patient still feels that he is sitting on the volcano. It is therefore important to have specific advice when the agitated patient seeks help. When a vitreous haemorrhage occurs, the patient should have complete rest for 24 to 48 hours, preferably sitting up in bed with eyes covered. This allows the bleeding to stop and the haemorrhage to settle at the bottom of the eye, sometimes revealing a bleeding point which may be suitable for treatment by photocoagulation. If the haemorrhage has not cleared at all during 48 hours, then there is no need to continue with this regime, but if there has been a little clearance, then further rest may be advisable. A vitreous haemorrhage may take very many months to clear and certainly dramatic methods for its removal should not be contemplated until it has been present for a year. There is no systemic therapy of value, and light coagulation blindly applied to the blood in the vitreous has not been shown to be effective. The injection of urokinase into the vitreous had been advocated by workers in Glasgow⁶ but it has received discouraging reports from a study carried out in Moorfields⁷.

Aspiration of vitreous, which is an old method, on the whole does not work since the clear vitreous tends to be aspirated leaving the murky substance behind. We have had success in removing haemorrhagic vitreous using either the open sky technique or Kasner⁸ or vitreous infusion suction cutter developed by Machemer^{9, 10} the techniques of which will be described subsequently. The patients must have at least perception of light, the intra-ocular pressure should be normal and, although some rubeosis of the iris is permissible, a rubeotic angle is probably a contra-indication to these procedures. Ultrasonic examination is of some value in establishing the state of the retina in these cases. (Fig 3).

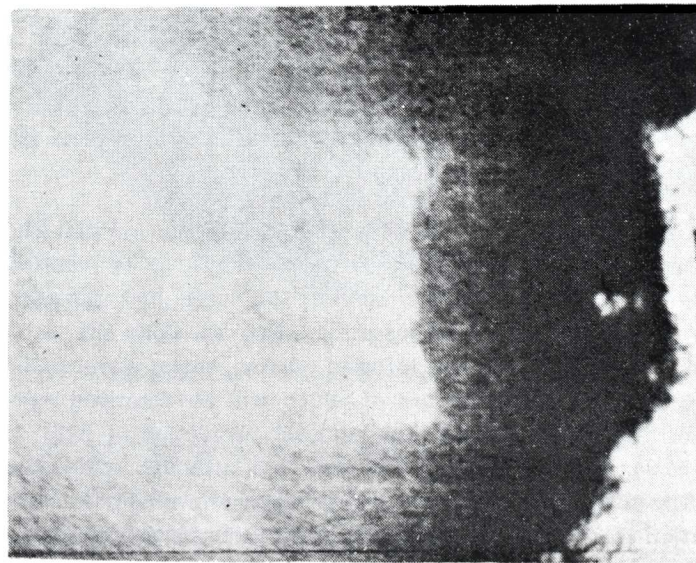
ROLL K. BLANCH

FIGURE 3

Ultrasonic examination, B scan, showing:



(a) Vitreous haemorrhage before vitrectomy;



(b) Axial clearing of opacity post-operatively.

8. *Retro-Vitreous Membrane*

A retro-vitreous membrane may form on the posterior surface of the detached vitreous from the region of the base and constitutes a formidable barrier to light. Such a vitreous membrane can be removed either by the open sky technique or a vitrectomy apparatus. It is important in both cases not to be too ambitious in removing this membrane. It is only necessary to expose the posterior retina since, if one goes too near the vitreous base, the dangers of causing a retinal detachment and retinal tears in the periphery are too great. In our experience these iatrogenic retinal detachments are particularly difficult to treat and may result in further activation of the diabetic retinopathy with vascular proliferation leading to a blind eye. However, with care, dramatic and remarkable results can be obtained by these operations. (Fig. 4, 5). In the Kasner technique a large limbal section is made, a broad iridectomy is performed and the lens is removed, whether it is clear or opaque. The vitreous is removed with the help of absorbable swabs until the posterior vitreous membrane is identified using a microscope with co-axial illumination. A hole is made into this membrane and extended so that the posterior retina becomes easily visible. The eye is then filled with Ringer's solution and closed. (Fig. 4) Scott, instead of making a large section, actually removes the cornea completely and then replaces it. This would seem a sensible variant of the technique.

More satisfactory, however, is using the vitreous infusion suction cutter. Although a number of workers suggested it is more satisfactory to use this instrument removing the lens, this is certainly not always necessary. In my opinion, it should be left if it is clear. The anterior vitreous is removed with the help of a microscope using co-axial illumination. We prefer to use the indirect ophthalmoscope for the posterior part of the eye. Areas of fibrous tissue in front of the retina can be removed by this means. When the operation is successful, the visual results, will, of course, depend upon the state of the retina, but again, dramatic results can be obtained. (Fig. 4). The eyes are remarkably quiet on the day after operation, and patients can often be discharged within a day or two of this procedure. Sometimes, however, light coagulation is required either at operation or during the immediate post-operative period if new vessels are exposed or bleeding occurs.

9. *Traction Detachments Due to Vitreous or Inter-Retinal Bands*
Provided it can be established that these bands are completely free of retina in a part of their course, and this can best be ascertained by a slit lamp biomicroscopy, it is reasonable to cut these with vitreous scissors such as the Grieshaber scissors, developed by Freeman.¹¹ Usually this procedure will have to be accompanied by an encircling procedure for retinal detachment. However, more often the bands really represent the condensed edge of a vitreous sheet and may be more satisfactorily dealt with by a vitrectomy apparatus. If they contain retina they must be left, in view of the danger of damaging the retina.

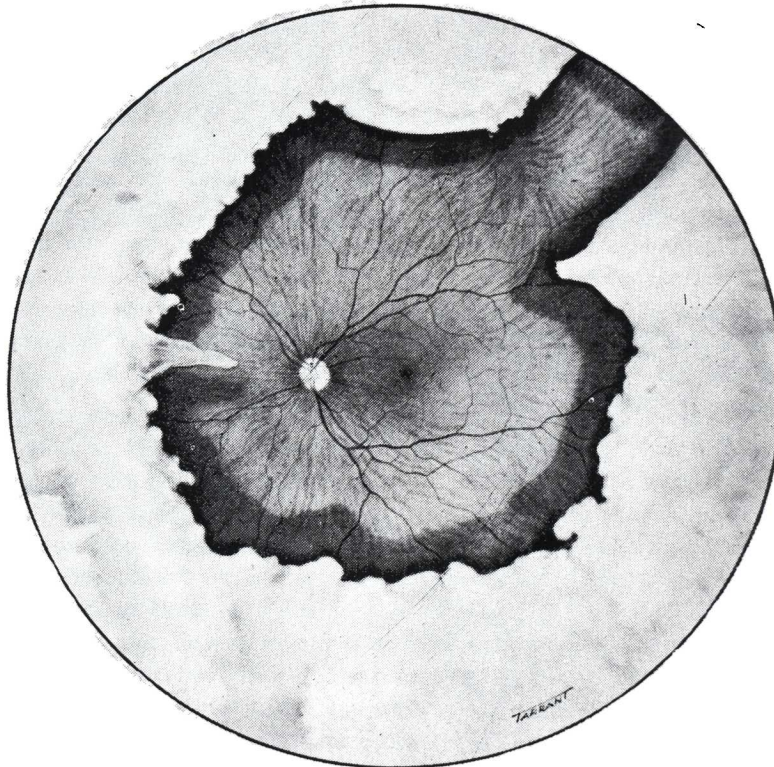


FIGURE 4

An eye after vitrectomy showing the margins of the posterior vitreous membrane left in situ.

THE MANAGEMENT OF VITREO-RETINAL

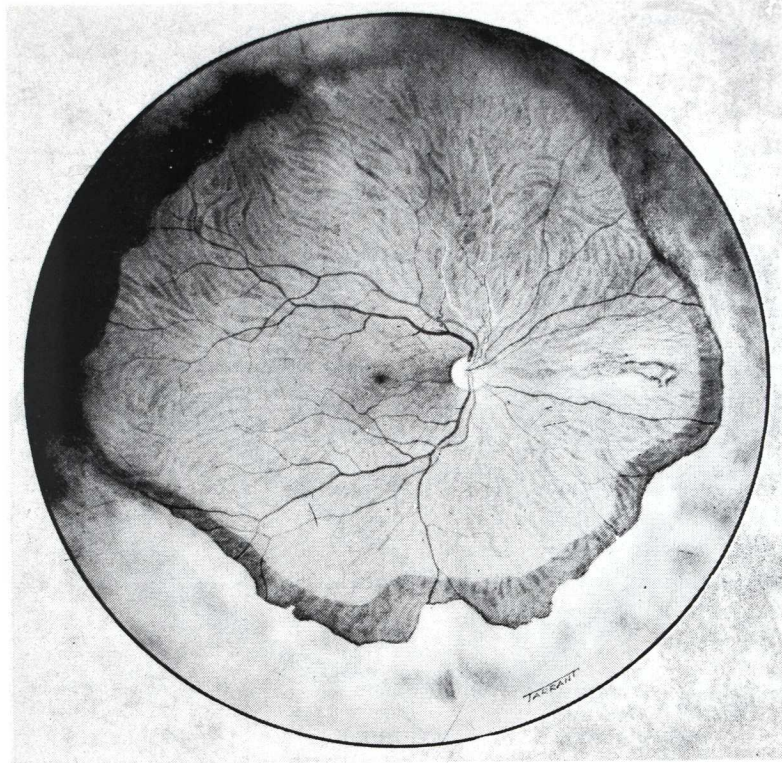


FIGURE 5

A similar case to Fig. 4.

10. *Posterior Traction Detachments Associated with Fibro-Vascular Proliferation from the Optic Disc*

This condition is beyond any form of treatment at the present time.

ROLL K. BLANCH

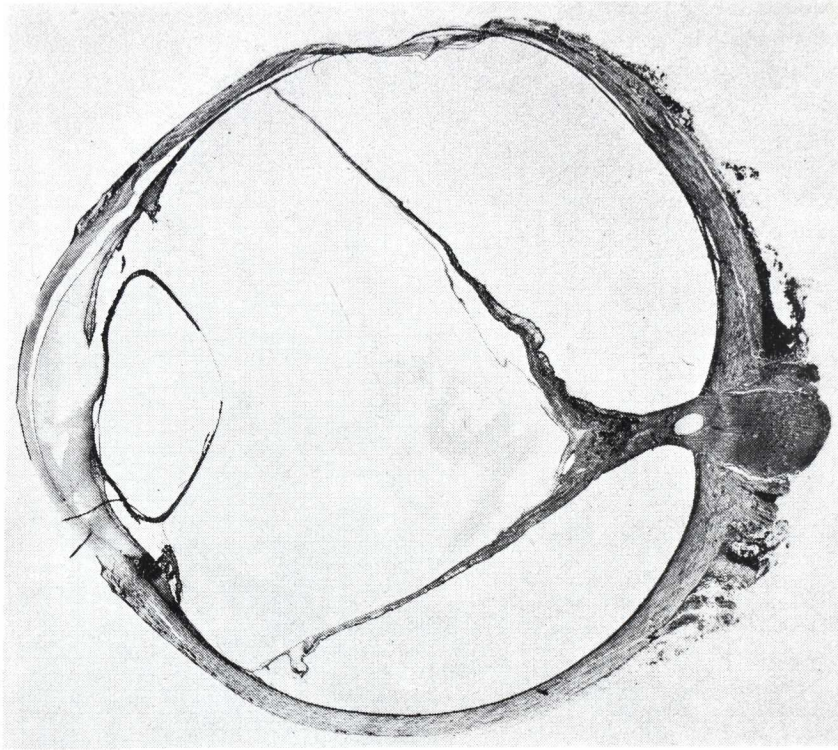







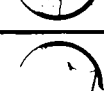





FIGURE 6

Section of a diabetic eye showing a fibro-vascular stalk arising from the optic disc associated with a retinal detachment.

It will be seen, therefore, if a logical assessment is made of the eyes of patients with advanced diabetic eye disease, there are certain groups that can be helped. (Table 1) It is important to know when to leave alone and when to treat. Traction detachments not involving the macula and fairly recent vitreous haemorrhages should not be treated. However, some types of retinal detachment and some forms of vitreous organization are certainly suitable for treatment by methods that are now available. Often the success of these methods is not permanent because, of course, the underlying condition of diabetes remains and the whole mechanism giving rise to the original complication may recur. However, even if sight is maintained for only a limited period of time, these procedures are justified.

THE MANAGEMENT OF VITREO-RETINAL

TABLE 1
RETINAL DETACHMENT (RD) IN DIABETES
DIAGNOSIS TREATMENT (Rx)

1		VITREOUS RETRACTION	NO Rx
2		OPERCULUM UP-DRAWN VEIN	PHOTOCOAGULATION (PLOMB IF RETINA DETACHED)
3		TRACTION RD NO HOLE MACULA ON	NO Rx WATCH
4		TRACTION RD NO HOLE MACULA OFF	ENCIRCLE, CRYO, DRAIN S.R.F. & INJECT AIR
5		NEW VESSELS FLAT RETINA	PHOTOCOAGULATION (NB AVOID FIBROUS TISSUE THREATENING MACULA)
6		INTER RETINAL FIBROSIS FLAT RETINA	NO Rx
7		INTER RETINAL FIBROSIS RD	CUT BAND IF PARTLY FREE OF RETINA → AS "4" IF NEEDED
8		VITREOUS HAEMORRHAGE	ACUTE. ABSOLUTE REST + EYE COVERED 48 hrs. > 1 Yr. → "9"
9		RETRO VITREAL MEMBRANE OLD VITREOUS HAEMORRHAGE	ULTRA-SOUND VITRECTOMY → "4" IF NEEDED
10		FIBRO VASCULAR TISSUE FROM DISC FLAT RETINA	? VITRECTOMY
11		FIBRO VASCULAR TISSUE FROM DISC R. D.	NO Rx

ROLL K. BLANCH

SUMMARY:

Since the ethiology and the natural course of a diabetic retinal detachment is much more complex than that of a simple retinal detachment, the author believes the study of the individual mechanism which produced the detachment is of great importance to decide the treatment to be administered in each case.

The author then considers the different development stages of a retinal detachment in diabetic retinopathies, discussing its management in each phase (see figure).

He ends by stating that the retinal detachments which do not compromise the macula, and the fairly recent vitreous hemorrhages must not be treated.

He emphasizes Machemer's vitrectomy techniques, stating that the success of such techniques may not be permanent due to the persistent diabetic conditions and to the possibility of a relapse of the whole pathological phenomenon.

J. M.

REFERENCES

- 1 HRUBI, K.: *Klinische Untersuchungen über das Verhalten des Glaskorpers bei Retinitis Proliferans*. V. Graefes. Arch. Ophthal., 144 435, 1942.
- 2 TOLENTINO, T., LEE, P. F., and SCHEPENS, C. L.: *Biomicroscopic Study of the Vitreous Cavity in Diabetic Retinopathy*. Arch. Ophthal., Chicago, 75: 238, 1966.
3. DAVIS, M. D.: *Vitreous Contraction in Proliferative Diabetic Retinopathy*. Arch. Ophthal., Chicago 74: 741, 1965.
- 4 OKUN, E. and FUNG, W. E.: *Therapy of Diabetic Retinal Detachment*, in Symposium on Retina and Retina Surgery from the New Orleans Academy of Ophthalmology (Mosby), St. Louis, 1969.
- 5 SCOTT, J. D.: *Surgery of Advanced Diabetic Retinopathy - Modern Problems*, in Ophthalmology, Vol. 8, p. 505 (S. Karger Base), 1968.

THE MANAGEMENT OF VITREO-RETINAL

- 6 FORRESTER, J. V. & WILLIAMSON, J.: **Lytic Therapy in Vitreous Haemorrhage.** Trans. Ophthal. Soc. U. K. 94, 583, 1974.
- 7 CLEARY, P. E., DAVIES, E. SHILLING, J. S., HAMILTON, A. M.: **Intra-Vitreous Urokinase in the Treatment of Vitreous Haemorrhage.** Trans. Ophthal. Soc. U. K. 94 587, 1974.
- 8 KASNER, D., MILLER, G. R., TAYLOR, W. H. SEVER, R. J. and NORTON, E. W. D.: **Surgical Treatment of Amyloidosis of the Vitreous.** Trans. Amer. Acad. Ophthal. Otolaryng. 72: 410, 1968.
- 9 MACHEMER, R. BUETTNER, H., NORTON, E. W. D., PAREL, J. M.: **Vitrectomy, a Pars. Plana Approach.** Trans. Amer. Acad. Ophthal. Otolaryng. 75: 813, 1971.
- 10 MACHEMER, R. and NORTON, E. W. D.: **Vitrectomy, a Pars. Plana Approach. II Clinical Experience.** Mod. Probl. Ophthal., Vol. 10, p. 178 (Karger, Basel), 1972.
- 11 FREEMAN, H., MCKENZIE and SCHEPENS, C. L.: **Vitreous Surgery. II. Instrumentation and Technique,** A.M.A. Arch. Ophthal, 77: 681-682, 1967.